

ISSN: 0976-3031

*International Journal of Recent Scientific
Research*

Impact factor: 5.114

**CAVERNOUS HEMANGIOMA OF ORBIT; IMAGING
FEATURES**



Krishna Kumar

Volume: 6

Issue: 10

**THE PUBLICATION OF
INTERNATIONAL JOURNAL OF RECENT SCIENTIFIC RESEARCH**

<http://www.recentscientific.com>

E-mail: recentscientific@gmail.com



ISSN: 0976-3031

Available Online at <http://www.recentscientific.com>

International Journal of Recent Scientific Research
Vol. 6, Issue, 10, pp. 6941-6946, October, 2015

**International Journal
of Recent Scientific
Research**

RESEARCH ARTICLE

CAVERNOUS HEMANGIOMA OF ORBIT; IMAGING FEATURES

Krishna Kumar

Department of Radiology & Imaging. DM Wayanad Institute of Medical Sciences. Naseera Nagar,
Meppadi P O, Wayanad. Kerala

ARTICLE INFO

Article History:

Received 15th July, 2015
Received in revised form
21st August, 2015
Accepted 06th September, 2015
Published online 28st
October, 2015

Key words:

Benign orbital mass, Cavernous hemangioma, Cavernous malformation, Doppler ultrasound, MRI, Orbital vascular lesion.

ABSTRACT

Cavernous Hemangioma (also known as cavernous malformation), although not true neoplasm, are the most common benign adult orbital tumor. MR imaging is particularly valuable for evaluation of orbital neoplasms, as it provides critical anatomic information about ocular structures involved, perineural spread, and intracranial extension. Cavernous Hemangioma typically appear as a well-circumscribed, ovoid intraconal mass on cross-sectional images.

We report a 30 years old female patient, presenting with swelling in the superio-medial aspect of left orbit since 6 years, diagnosed to have cavernous hemangioma. Clinical symptoms, Imaging features & Management of Cavernous Hemangioma are herewith discussed.

Copyright © Krishna Kumar. 2015, This is an open-access article distributed under the terms of the Creative Commons Attribution License, which permits unrestricted use, distribution and reproduction in any medium, provided the original work is properly cited.

INTRODUCTION

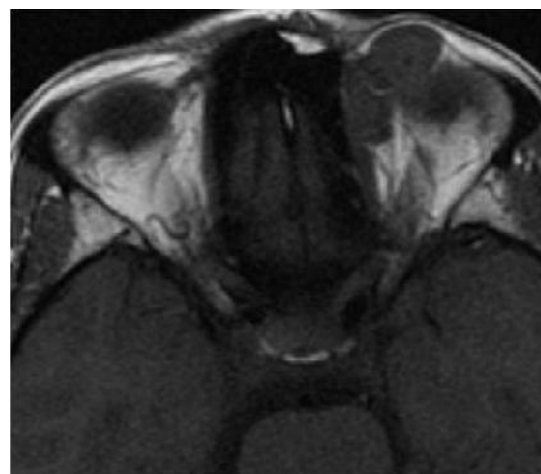
Cavernous hemangioma' is a term that is widely used to describe a solitary, encapsulated venous-lymphatic malformation, the most common vascular lesion of the orbit [1]. Cavernous malformations (CM) are thought to be congenital vascular anomalies that are present at birth, do not spontaneously involute, and grow slowly over time [2].

This tumor occurs in females more frequently, than in males and has its peak incidence in early middle age [3], and it may enlarge during pregnancy [4]. Painless and progressive reducible unilateral proptosis causing a variable degree of hyperopia is the usual clinical presentation [5, 6] and amaurosis fugax can occur [7]. We report a 30 years old female patient with pathologically proven cavernous hemangioma of orbit. The Clinical, pathological, specific MRI and Doppler ultrasound findings are discussed.

Case Report

A 30 years old female patient presented to the outpatient clinic with a swelling in the superio-medial aspect of left orbit since 6 years, was referred for MRI evaluation.

MRI imaging (1.5Tesla Signa GE) and trans-orbital Doppler ultrasound (Voluson GE) evaluation of the left orbit was done. The patient was examined with T1 and T2 Weighted spin echo sequences, before and after administration of intravenous Gadolinium (0.1 mmol/kg) in axial, coronal and sagittal planes. Delayed contrast imaging was done at the end of 10 minutes. Fat saturation prepulse was given after Gadolinium enhanced delayed study. The imaging criteria analyzed were; location, size, margins, form, signal and echogenicity of the lesion.



*Corresponding author: **Krishna Kumar**

Department of Radiology & Imaging. DM Wayanad Institute of Medical Sciences. Naseera Nagar, Meppadi P O, Wayanad. Kerala

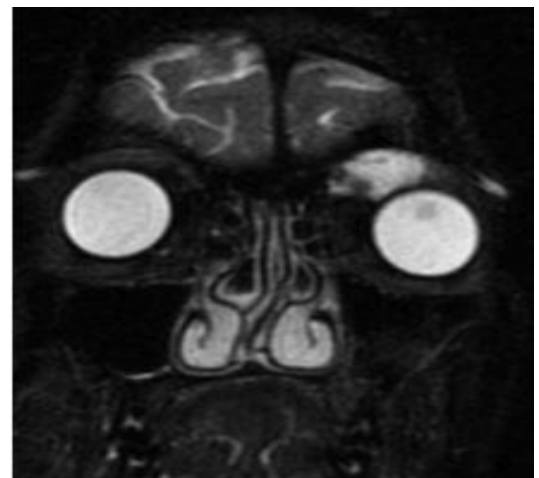
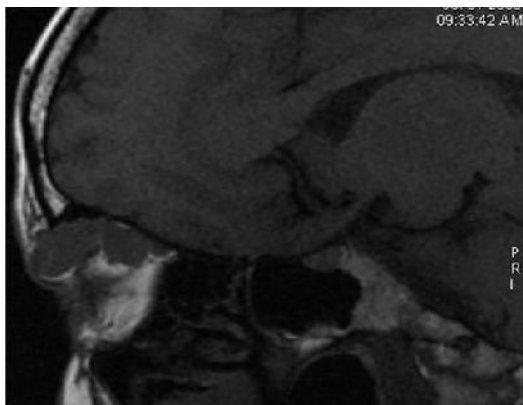
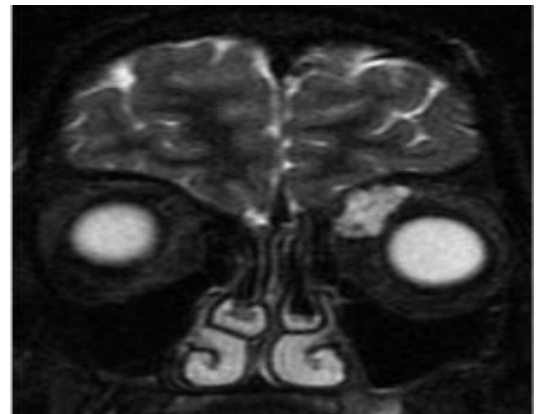
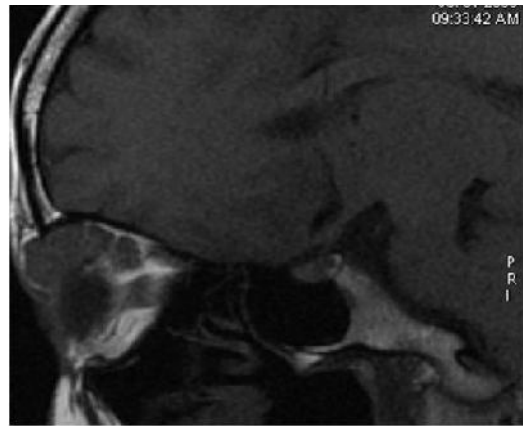
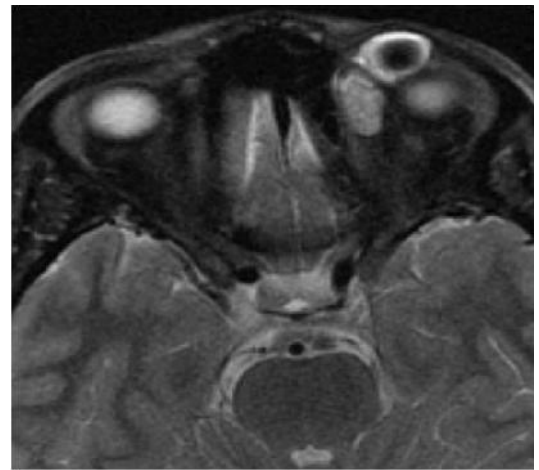
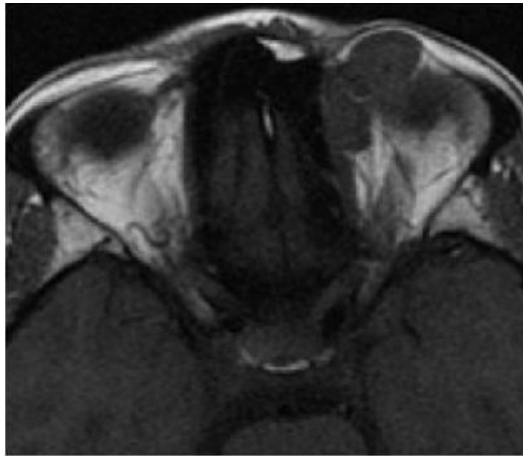
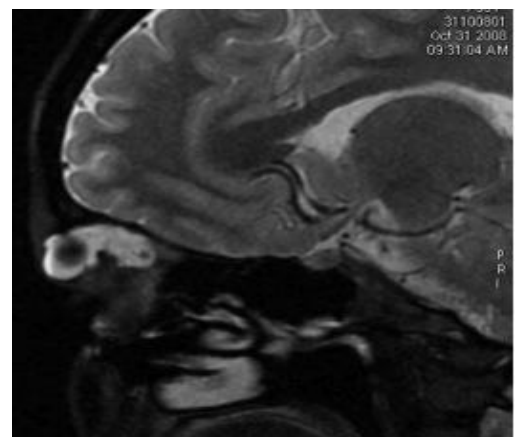
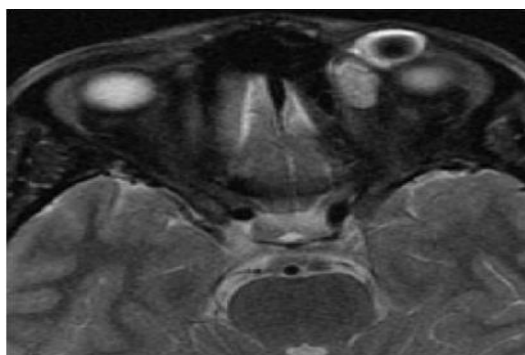


Fig. 1(a-e). 30 year old woman with cavernous hemangioma.

Conventional axial (a–c) and sagittal (c,d) images show a lobulated homogeneous isointense signal intensity intraconal lesion with internal small rounded hypointensity on unenhanced T1-weighted fast spin-echo images.



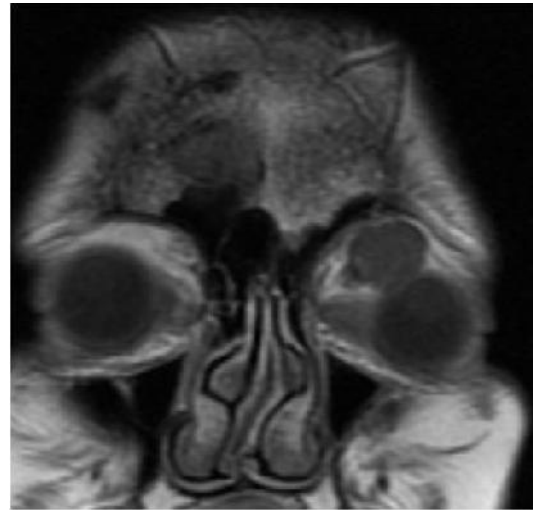
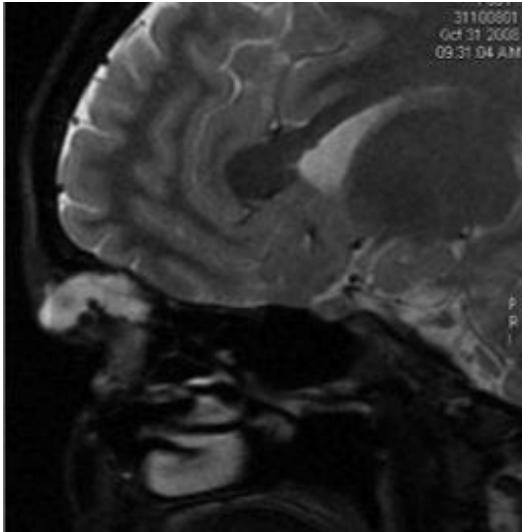


Fig. 2. Cavernous hemangioma (solitary encapsulated venous-lymphatic malformation).

Axial T2W (a,b), Coronal(c,d) and Sagittal (e,f) shows an ovoid, lobulated homogeneous hyperintense intraconal mass with small internal rounded hypointensity that distorts the medial rectus muscle.

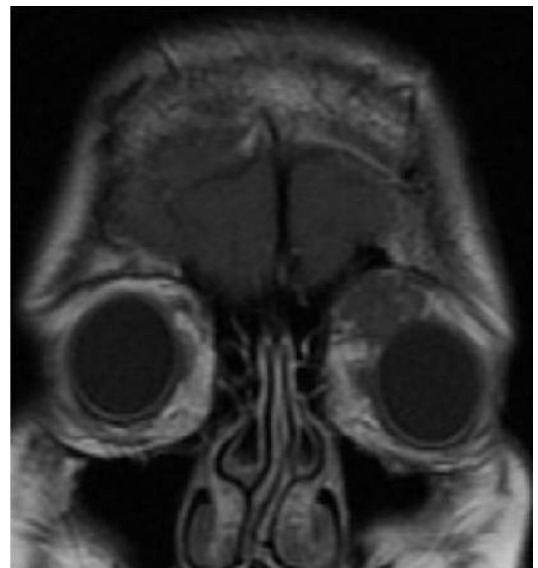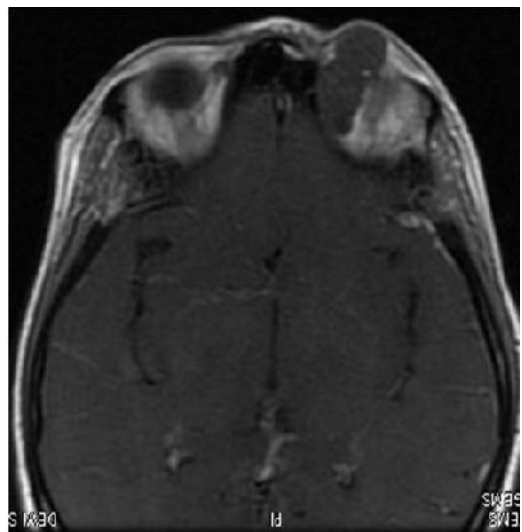
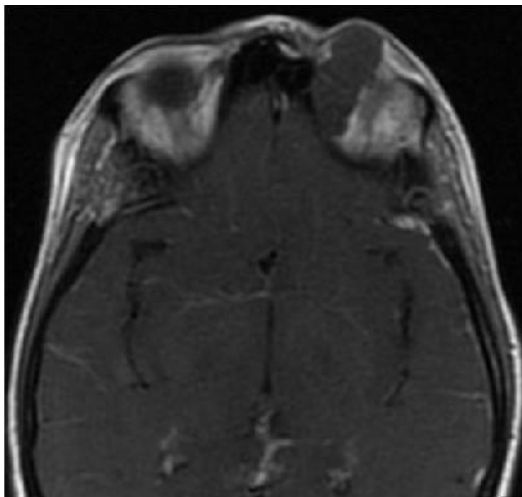

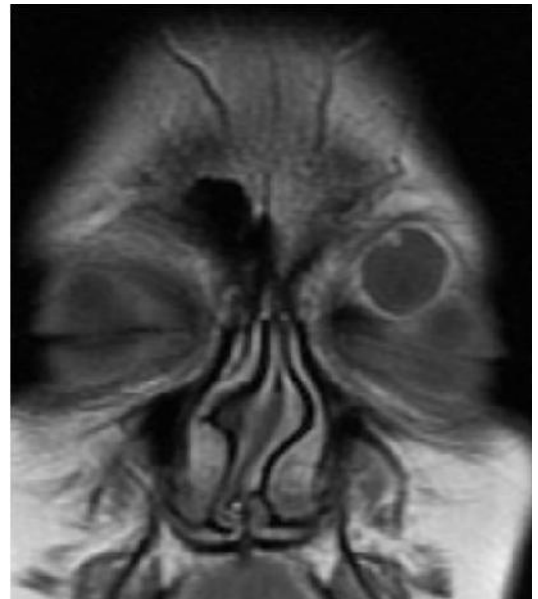
Fig.3. Axial T1 (a,b) and Coronal (c,d,e) with Gadolinium contrast, obtained immediately after contrast injection, shows peripheral nodular enhancement.

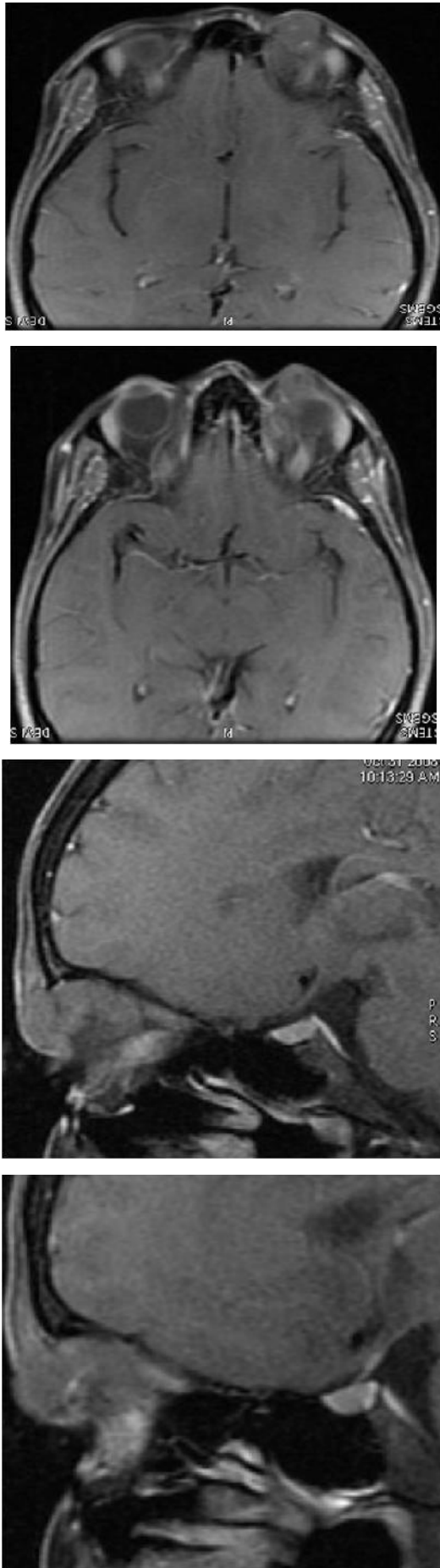


Fig.4. Axial (a,b) and Sagittal(c,d) fat suppressed T1W with contrast, obtained 10 min after contrast injection, shows more uniform contrast enhancement.

This slowly progressive nodular enhancement is typical of cavernous hemangioma, though also occasionally seen in schwannoma.

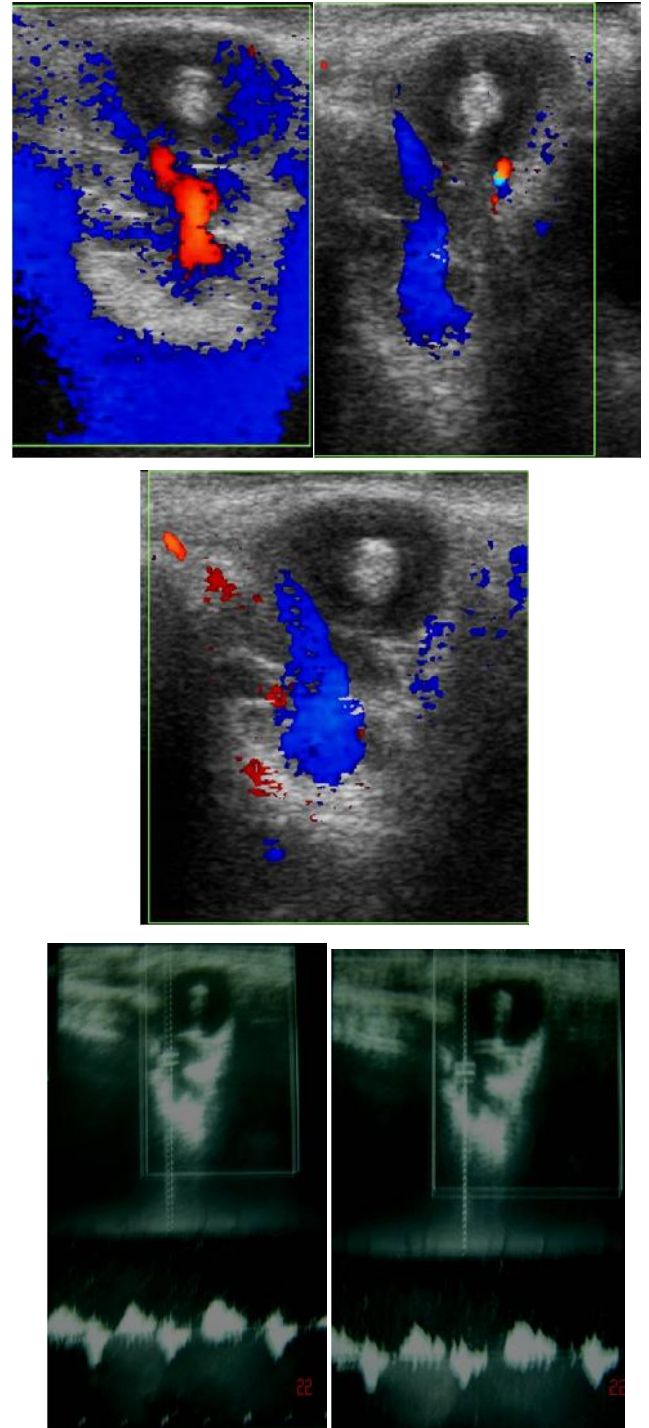


Fig.5.(a-e). Trans-orbital colour duplex Doppler Ultrasound with high frequency probe shows an oval hypointense mass with internal small rounded hyperechoic focus without acoustic shadowing and absent vascularity suggestive of phlebolith. The central retinal artery and superior ophthalmic vein is

outlined. Normal venous blood flow seen in superior ophthalmic vein.

DISCUSSION

Although not true neoplasms, Cavernous Malformations (CM) are the most common benign orbital mass in adults with female predominance.

In the orbit, Cavernous Hemangioma represents 80% of the angiomatous lesions followed by Capillary hemangioma, Lymphangioma and Hemangiopericytomas [10].

Because these lesions are slow growing, progressive painless proptosis is the most common clinical sign, at patient presentation. However, some patients will present with abrupt orbital enlargement and acute-onset proptosis, caused by cytokine and hormonal stimulation at puberty or during pregnancy [2].

Although rare, involvement of the orbital apex can cause compressive optic nerve neuropathy, which leads to monocular vision loss .Other less common symptoms include pain, eyelid swelling, diplopia, or a palpable lump [2].

The most frequent locations are the retrobulbar muscle cone, especially the lateral aspect of the intraconal space [9]. However, a small minority (less than 10%) of these lesions are extraconal [3].

At microscopy, cavernous malformations appear as, thin walled sinusoidal spaces lined by endothelial cells and separated by irregular fibrous connective tissue septa without apparent arterial supply or venous drainage [10]. Because of its slow flow intravascular thrombosis is often seen, with occasionally associated phleboliths [3].

Cavernous hemangiomas rarely bleed [8], due to firmer texture from the surrounding support of rich fibrous tissue [10]. Orbital Cavernous Hemangiomas are typically solitary and unilateral, though multifocal and bilateral lesions have been reported [5, 10–13].

Cavernous malformations tend to displace and surround adjacent structures, such as extraconal muscles and the optic nerve, rather than cause direct invasion. Osseous remodeling may be present, although bone erosion is rare [9].

At multiphase CT, enhancement of cavernous malformations is poor on early arterial phase images, owing to the scant arterial supply in these lesions [9]. Delayed venous phase images demonstrate progressive filling of the mass from periphery to center, with complete filling within 30 minutes (9, 14). This enhancement pattern may permit differentiation of cavernous malformations from other vascular lesions with rich arterial supply, such as capillary hemangioma, hemangiopericytoma, and arteriovenous malformations [2]. Concerns related to the increased radiation exposure of multiphase CT, make this technique relatively less desirable.

Nonenhanced CT shows homogeneous soft tissue density, and may show small calcifications or phleboliths [15].

MRI Cross-sectional imaging can aid in the diagnosis and evaluation of orbital neoplasms, supplementing findings from fundoscopic and clinical ophthalmologic examinations.

At magnetic resonance (MR) imaging performed with T1-weighted sequences, cavernous malformations are isointense relative to muscle; the lesions appear uniformly hyperintense on T2-weighted images, with no flow voids. Internal septations may be identified on T2-weighted images [16]. MR classically demonstrates nodular enhancement on early post-contrast images, and progressive accumulation of contrast on delayed post-contrast images [9]. The thin, regular circumferential hypointense rim at the periphery of the tumor is thought to correspond to the fibrous capsule surrounding the lesion.

MR angiography and CT angiography are generally not able to identify the feeding vessels of a cavernous hemangioma, likely due to their small caliber.

Colour Doppler Imaging (CDI) of Cavernous Hemangiomas of the orbit usually show only very little to almost no flow and extremely low venous flow velocities throughout the lesion.

Differential diagnosis include- Venous varix, schwannoma, optic nerve sheath meningioma, and lymphoma.

Surgical treatment is indicated in symptomatic patients ,always in case of compression of optic nerve ,while those asymptomatic should be followed clinically and radiologically [3,17,18] .Total excision is not mandatory, especially when difficult, because recurrences are extremely rare and the growth very slow [17,18].

Our patient underwent surgery with pathologically proven Cavernous Hemangioma.

CONCLUSION

From the analysis of the MR appearance of an intraconal, well defined mass, associated homogenous signal, isointense to muscle on T1 weighted sequence, hyperintense on T2 weighted sequence, and especially delayed progressive filling on Gadolinium enhanced sequences, the diagnosis of cavernous hemangioma may be highly suggestive in a patient presenting with slow growing mass in the supero-medial aspect of orbit. Use of MR imaging is especially valuable for assessing the extent of disease, precise lesion location, involved orbital compartments, spread to the orbital apex or along perineural pathways, and associated intracranial abnormalities provide information beyond what can be seen at fundoscopy and clinical ophthalmologic examinations and facilitate appropriate treatment.

References

1. Shields JA, Bakewell B, Augsburger JJ, Flanagan JC. Classification and incidence of space-occupying lesions

- of the orbit. A survey of 645 biopsies. *Archiv Ophthalmol* 1984; 102(11):1606–11.
2. Smoker WR, Gentry LR, Yee NK, Reede DL, Nerad JA. Vascular lesions of the orbit: more than meets the eye. *RadioGraphics* 2008; 28(1):185–204.
 3. Harris GJ, Jakobiec FA. Cavernous hemangioma of the orbit. *J Neurosurg* 1979; 51:219–228.
 4. Dinakar I, Naik RT, Purohit AK, Ratnakar KS. Cavernous hemangioma of the orbit: a case report. *Indian J Pathol Microbiol* 1993; 36:318–321.
 5. Ruchman MC, Flanagan J. Cavernous hemangiomas of the orbit. *Ophthalmology* 1983; 90:1328–1336.
 6. D'Hermies F, Elmaleh C, Mourier K, et al. Cavernous hemangioma of the orbit [in French]. *J Fr Ophthalmol* 1993; 16:195–198.
 7. Brown GC, Shields JA. Amaurosis fugax secondary to presumed cavernous hemangioma of the orbit. *Ann Ophthalmol* 1981; 13:1205–1209.
 8. Zenobii M, Galzio RJ, Lucantoni D, Caffagni E, Magliani V. Spontaneous intraorbital hemorrhage caused by cavernous angioma of the orbit. *J Neurosurg Sci* 1984; 28 (1):37–40.
 9. Ansari SA, Mafee MF. Orbital cavernous hemangioma: role of imaging. *Neuroimaging Clin N Am* 2005; 15(1):137–158.
 10. Thorn-Kany M, Arrue P, Delisle MB, Lacroix F, Lagarrigue J, Manelfe C. Cavernous hemangiomas of the orbit: MR imaging. *J Neuroradiol. J Neuroradiol* 1999; 26(2):79–86.
 11. Wolin MJ, Holds JB, Anderson RL, Mamalis N. Multiple orbital tumors were cavernous hemangiomas. *Ann Ophthalmol* 1990; 22(11):426–8.
 12. Sullivan TJ, Aylward GW, Wright JE, Moseley IF, Garner A. Bilateral multiple cavernous haemangiomas of the orbit. *The Brit J Ophthalmol* 1992; 76(10):627–9.
 13. Shields JA, Hogan RN, Shields CL, Eagle Jr RC, Kennedy RH, Singh AD. Bilateral cavernous haemangiomas of the orbit. *The Brit J Ophthalmol* 2000; 84(8):928.
 14. Yousem DM, Zimmerman RD, Grossman RI. *Neuroradiology: the requisites*. Philadelphia, Pa: Mosby, 2010.
 15. Mafee MF, Putterman A, Valvassori GE, Campos M, Capek V. Orbital space-occupying lesions: role of computed tomography and magnetic resonance imaging. An analysis of 145 cases. *Radiol Clin North America* 1987; 25(3):529–59.
 16. Wang Y, Xiao LH. Orbital schwannomas: findings from magnetic resonance imaging in 62 cases. *Eye (Lond)* 2008; 22(8):1034–1039.
 17. Gloor B, Kalman A. Neoplastische raumverdrangungen in der orbita.1. Übersicht; Hamangiom, Lymphangiom, und embryonales rhabdomyosarkom. *Kln Mbl Augenheilk* 1992; 201:291-301.
 18. Gunalp I, Gunduz K. Vascular tumors of the orbit. *Documenta Ophthalmologica* 1995; 89:337-345.

How to cite this article:

Krishna Kumar.2015, Cavernous Hemangioma of Orbit; Imaging Features. *Int J Recent Sci Res.* 6(10), pp. 6941-6946.

*International Journal of Recent Scientific
Research*

ISSN 0976-3031



9 770576 303009