



RESEARCH ARTICLE

**CHLORPYRIFOS INDUCED HISTOLOGICAL CHANGES IN THE LIVER OF TILAPIA  
(*OREOCHROMIS MOSSAMBICUS*)**

**<sup>1</sup>Muttappa K\*, <sup>1</sup>Reddy, H.R.V., <sup>1</sup>Padmanabha, A., <sup>2</sup>Shridhar Bhatt, <sup>2</sup>Prabhudeva. K.N.,  
<sup>2</sup>Basavaraju, Y., <sup>1</sup>Gangadhar Gowda, <sup>2</sup>Rajanna, K. B., <sup>2</sup>Chethan, N**

<sup>1</sup>Department of Aquatic Environment Management, College of Fisheries, Mangalore - 575 002, India

<sup>2</sup>Fisheries Research and Information Center, Hebbal, Bangalore-560 094, India

ARTICLE INFO

**Article History:**

Received 2<sup>nd</sup>, July, 2015  
Received in revised form 10<sup>th</sup>,  
July, 2015  
Accepted 4<sup>th</sup>, August, 2015  
Published online 28<sup>th</sup>,  
August, 2015

ABSTRACT

A bioassay was conducted to determine the lethal toxicity (LC<sub>50</sub>) of commercial grade Organophosphate insecticide, Chlorpyrifos (20% EC) on Tilapia (*Oreochromis mossambicus*). The 96 h (LC<sub>50</sub>) for Chlorpyrifos (20% EC) was found to be 0.022 ppm. For sublethal toxicity study, the fishes were exposed to two sublethal concentrations (i.e 1/5<sup>th</sup> of LC<sub>50</sub> and 1/10<sup>th</sup> of LC<sub>50</sub>) for 21 days. Histopathological changes in liver ranged from vacuolization, necrosis, aggregation of melanomacrophage, increase in number of kuffer cells at different time of exposure viz. 7, 14 and 21 days.

**Key words:**

Histology, Chlorpyrifos, Lethal toxicity and *Oreochromis mossambicus*

**Copyright © Muttappa K et al.**, This is an open-access article distributed under the terms of the Creative Commons Attribution License, which permits unrestricted use, distribution and reproduction in any medium, provided the original work is properly cited.

INTRODUCTION

Pesticides have been one of the most effective weapons discovered by man to protect agricultural products from pests. However, they are the major cause of concern for aquatic environment due to their toxicity, persistency and tendency to accumulate in the organisms (Joseph and Raj, 2010) and it is difficult to remove them from any aquatic ecosystem.

Chlorpyrifos (O, O-diethyl-O-3, 5,6-trichlor-2-pyridyl phosphorothioate; CPF) is a broad spectrum organophosphate insecticide widely used to control foliar insects in agricultural crops (Rusyniak and Nanagas, 2004) and subterranean termites (Venkateswara Rao et al., 2005). It is the second highest selling organophosphate insecticide and is more toxic to fish than organochlorine compounds (Tilak et al., 2001). Fishes have greater sensitivity to changes in the aquatic environment (Vinodhini and Narayanan, 2008). Capacity to accumulate large quantity of pollutants and important link in the food chain, fishes are often used as indicator organisms to monitor quality of aquatic systems the world over (Rajkowska and Protasowicki, 2011).

Histopathological investigations have long been recognized to be reliable biomarkers of stress in fish. These can be used as biomonitoring tools or indicators of health in toxicity studies since they provide early warning signs of disease and the health of aquatic environment (Meyers and Hendricks, 1985). The toxic effects of pesticides on various tissues and organs of fishes have been studied by many researchers. Some of these include, Atrazine to *Labeo rohita* (Jayachandran and Pugazhendy, 2009), Cypermethrin to *Tor putitora* (Ullah et al., 2014d), *Corydoras melanistius* (Santos et al., 2012), Dimethoate to *Putius ticto* (Marutirao, 2012), Hostathion to *Channa gachua* (Jha et al., 2014). Similarly, the studies on histopathological changes in fishes have been carried out by Das and Mukerjee, (2000) Cengiz and Unlu, (2002), Parashar and Banerjee, (2002), Johal et al. (2007), Kunjamma et al. (2008), Velmurugan et al. (2009), Rani and Venkataramana, (2012).

In view of the above, it was felt that it would be worthwhile to study the histological changes in liver of fish which would throw a clear light on the extent of effect that it causes. Hence in the present work, we studied the toxic effects of Chlorpyrifos on histological changes in liver of fish, *Oreochromis mossambicus*.

\*Corresponding author: **Muttappa K**

Department of Aquatic Environment Management, College of Fisheries, Mangalore - 575 002, India

## MATERIALS AND METHODS

*Oreochromis mossambicus* (2-3 cm) fry were acquired from Chintamani fish farm, Chickaballapur district, Karnataka and transported to the FRIC fish farm, Bangalore in well oxygenated polythene bags containing clean pond water and these were allowed to grow in fish pond till they attained fingerling size with artificial feeding. After attaining fingerling size (9-10 cm), they were collected and brought to laboratory and released into freshwater aquariums of 50 liter capacity (10 No's each) for proper acclimation. The fishes were fed every 24 hr with commercial feed. The walls of the holding tank were thoroughly cleaned periodically to avoid fungal growth. The excreta were siphoned off on a daily basis to prevent the buildup of ammonia in the medium. Fishes were conditioned for 10 days before employing them for the experiments. The tanks were kept in the laboratory, the temperature of the water was  $28 \pm 1^{\circ}\text{C}$  and the dissolved oxygen level was 7-7.5 ppm. The pH of the water ranged from 6.9-7.5. Individuals measuring  $9 \pm 0.5$  cm in total length and weighing  $13 \pm 0.5$  g were selected for the present study.

Lethal toxicity was carried out by following the standard guidelines (APHA 2005) to determine the lethal ( $\text{LC}_{50}$ ) level of toxicants using static system for Cadmium and static renewal for Chlorpyrifos. Laboratory conditioned fishes of uniform size were selected to assess the lethal concentration of the toxicant. Each experimental container was of 50 liter capacity, made of glass. Ten fish each were accommodated in 45 liters of test solution. Duplicates and appropriate controls were run for each set of experiment. Dead fishes were removed immediately from the test medium. The percentage mortality of fishes was taken into account for 96 h. Three replicates were performed for each concentration. The 96 h  $\text{LC}_{50}$  value of the mortality in each exposure concentration of Cadmium, Chlorpyrifos and Cadmium +Chlorpyrifos were recorded and tested by probit analysis program as described by Finney (1971).

### Histological Estimation

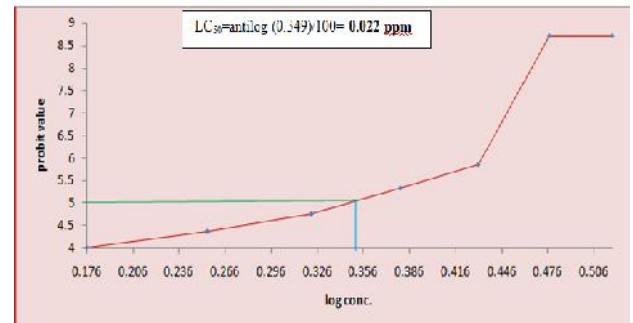
The experiment on the Histological changes in tilapia was carried out in a glass aquarium of 50 l capacity. The Histological changes in liver of fish treated with sub lethal concentration ( $\text{LC}_{50}$ ) of Chlorpyrifos were analysed after 7, 14 and 21 days of exposure. After the experimental period, the fishes were killed by pithing (by damaging the brain and severing the spinal cord between the head and trunk region using a sharp needle). The liver tissue was removed and immediately fixed in 10 % neutral buffered formalin and then processed for microtome sectioning at  $5\mu\text{m}$  and stained with hematoxylin and eosin and mounted in DPX.

## RESULTS

The concentration at which 50% survival/mortality occurred was taken as a lethal concentration ( $\text{LC}_{50}$ ). The 96 h  $\text{LC}_{50}$  for Chlorpyrifos was found to be 0.022 ppm for (Table 1 and Fig. 1.)

**Table 1** Determination 96hr  $\text{LC}_{50}$  of Cadmium in *Oreochromis mossambicus*

Conc. (ppm)	No. of fishes used	Mean % Mortality
0.015	10	16
0.018	10	26
0.021	10	40
0.024	10	63
0.027	10	83
0.03	10	100
0.033	10	100

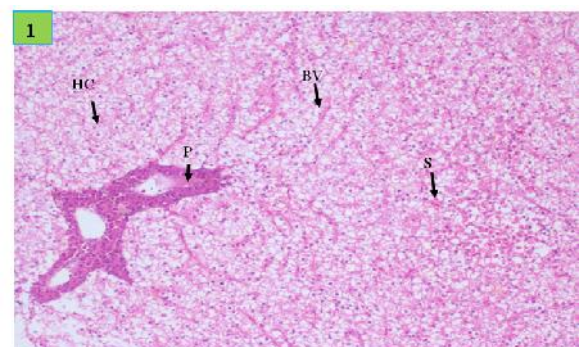


**Fig. 1** The 96 h lethal concentration ( $\text{LC}_{50}$ ) of Chlorpyrifos (20% EC) for Tilapia (*Oreochromis mossambicus*).

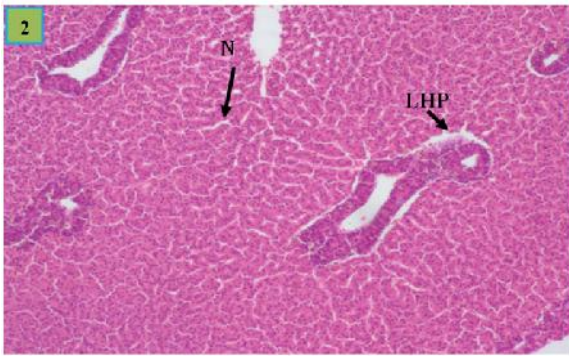
### Histological changes in liver

An insight into the liver of control fish, registered well structured hepatocytes and no deviation in pathological changes, which was evident in histological studies (Plate 1).

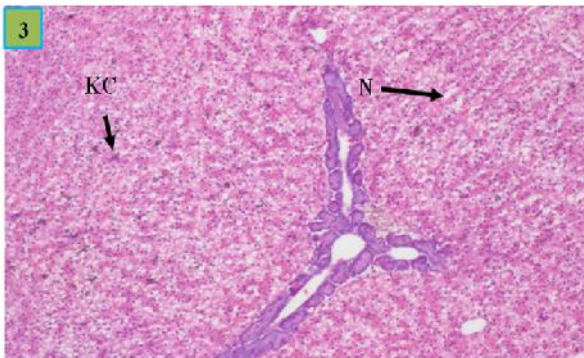
When tilapia fingerlings were exposed to  $1/5^{\text{th}}$  of  $\text{LC}_{50}$  of Chlorpyrifos, mild necrosis and loss of contact between hepatocyte and pancerocyte were documented after 7 days of exposure (Plate 2). Increased number of kupffer cells, mild necrosis was evident after 14 days of exposure (plate 3). Severe vacuolar degeneration was observed after 21 days of exposure of tilapia to Chlorpyrifos (Plate 4). When toxicant strength was reduced  $1/10^{\text{th}}$  of  $\text{LC}_{50}$  of Chlorpyrifos, aggregation of melanomacrophage, mild necrosis were evident in tilapia fingerlings exposed for 7 days (Plate 5). On 14 day showed vacuolar degeneration and congestion of liver (Plate 6). Further, aggregation of melanomacrophage, pyknotic nuclei and severe vacuolar degeneration were evident after 21 days of exposure (Plate 7). Among the two sub lethal concentrations of Chlorpyrifos,  $1/5^{\text{th}}$  of  $\text{LC}_{50}$  of this caused more severity to the liver structure.



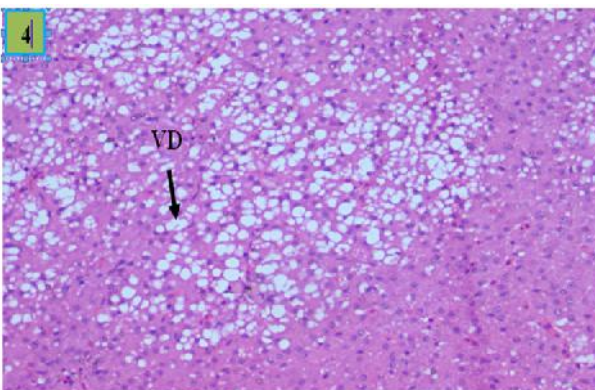
**Plate 1** Showing liver of control fish : Hepatic cell (HC), hepatopancreatic tissue (P), blood vessels (BV) and blood sinusoids(S). (H&E X 200).



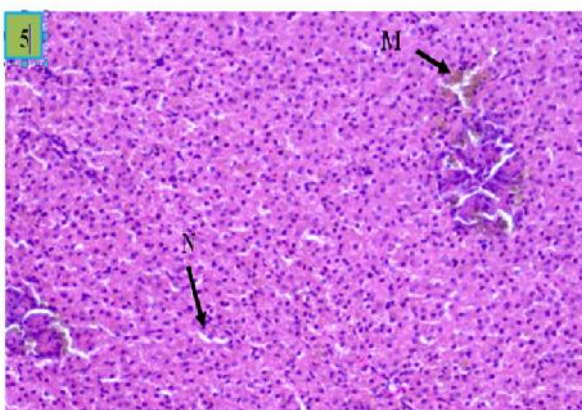
**Plate 2** Showing liver of fish exposed to 1/5<sup>th</sup> of LC<sub>50</sub> for 7 days : mild necrosis (N) and loss of contact between hepatocyte and pancreaticocyte (LHP). (H&E X 200)



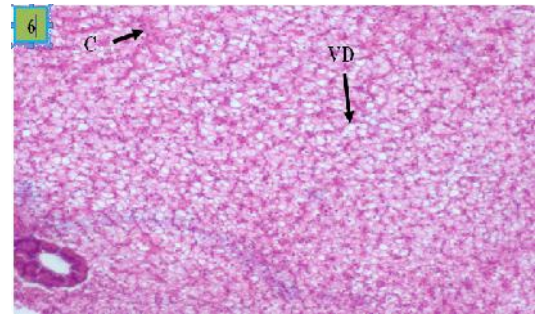
**Plate 3** Showing liver of fish exposed to 1/5<sup>th</sup> of LC<sub>50</sub> for 14 days : Necrosis (N), Congestion (C) and damage of



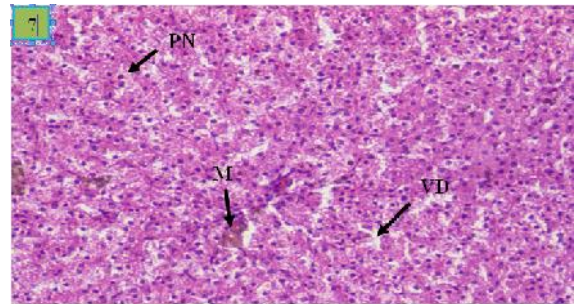
**Plate 4** Showing liver of fish exposed to 1/5<sup>th</sup> of LC<sub>50</sub> for 21 days : Severe vacuolar degeneration (VD) (H&E X 200)



**Plate 5** Showing liver of fish exposed to 1/10<sup>th</sup> of LC<sub>50</sub> for 7 days : melanomacrophage (M), mild necrosis (N). (H&E X 200)



**Plate 6** Showing liver of fish exposed to 1/10<sup>th</sup> of LC<sub>50</sub> for 14 days : vacuolar degeneration (VD), congestion of sinusoids (C). (H&E X 200)



**Plate 7.** Showing liver of fish exposed to 1/10<sup>th</sup> of LC<sub>50</sub> for 21 days : Aggregation of Melanomacrophage (M), Pyknotic nuclei (PN) and severe vacuolar degeneration (VD). (H&E X 200)

## DISCUSSION

There are some basic pathologies that pollutants in general may cause to fish liver like, swelling, disorganisation of hepatic cords, increased level of mitosis in liver parenchyma cells, changes in nuclear size and shape, nuclear migration of nuclei and focal necrosis (Hibya, 1982).

Morphological and histological alterations related to pesticide toxicity in the liver of fish have shown that the substances cause severe damage to the liver cells (Ortiz *et al.*, 2003). Liver is an important organ of detoxification and biotransformation process and due to these reasons the hepatic cells are damaged severely. Several works have reported degenerative changes in hepatic tissue subjected to pollution by various pesticides and insecticides (Gill *et al.*, 1990; Pandey *et al.*, 1993; Tilak *et al.*, 2005; and Sakr and Jamal Al Lail, 2005). Radhaiah and Jayantha Rao (1992) reported moderate cytoplasmic degeneration in hepatocytes, formation of vacuoles, rupture of blood vessels and picnotic nuclei in the liver of *Tilapia mossambica* exposed to fenvalerate.

The liver of pesticide treated fish showed dilation of blood sinusoids, vacuolization, disintegration of cell boundaries and necrosis. The present results are in agreement with those observed by many authors who studied the effects of different pollutants on fish liver (Mohamed, 2001; Ptashynski *et al.*, 2002 and Fanta *et al.*, 2003). According to Rodrigues *et al.* (2001) the liver is an organ that frequently undergoes changes when exposed to insecticide at sublethal doses. The changes may be attributed to direct toxic effects of pollutants on hepatic cells, since the liver is the site of detoxification of all types of toxic substances (Soufy *et al.*, 2007).

## CONCLUSION

The finding of the present study indicates that the biochemical and histological changes observed serve as biomarkers for assessing pesticide toxicity in aquatic environments.

## References

- APHA (American Public Health Association). 2005. Standard methods for examination of water including bottom sediments and sludges. Standard Methods, (19<sup>th</sup> ed.), 874
- Cengiz, E.I. and Unlu, E. 2002. Histopathological changes in the gills of mosquitofish, *Gambusia affinis* exposed to Endosulfan. B. Environ. Contam. Tox. 68: 290-296
- Das, B.K. and Mukherjee, S.C. 2000. A Histopathological study of carp, *Labeo rohita* exposed to hexachlorocyclohexane. Vet. Arhiv. 70(4): 169-180
- Fanta, E., Rios, F., Romao, S. Vianna, A. and Freiberger, S. 2003. Histopathology of the fish *Corydoras paleatus* contaminated with sublethal levels of organophosphorus in water and food. *Ecotoxicol. Environ. Safety*, 54(2):119-130.
- Finney, O. J., 1971. Probit analysis, 3<sup>rd</sup> edn. Cambridge University Press, 21.
- Gill, T. S., J. Pande, H. and Tewarj, 1990. Sublethal effects of an organophosphorus insecticide on certain metabolite levels in a freshwater fish, *Puntius conchoniensis* (Hamilton). *Pestic. Biochem. Physiol.* 36 (3): 290-299.
- Hibya, T., 1982. An Atlas of Fish Histology: Normal and Pathological Features, pp. 82-90. Tokyo, Kodansha and Gustav Fischer Verlag, 147p. in the liver of an estuarine mullet, *Liza parsia* by mercuric chloride and DDT. *Indian J. Fish.* 43(3): 277-284.
- Jayachandran, K. and Pugazhendy, K. 2009. Histopathological Changes in the Gill of *Labeo rohita* (Hamilton) fingerlings exposed to Atrazine. *Amer-Eruasian. J. Sci. Res.* 4(3): 219-221
- Jha, J.K., Ranjana kumar, P. and Mishra, A.P. 2014. Histopathological changes in the gills of *Channa gachua*, an air breathing teleost after short term exposure of Hostathion. *Bioscane.* 9(3): 925-929
- Johal, M.S., Sharma, M.L. and Ravneet. 2007. Impact of low dose of organophosphate, Monocrotophos on the epithelial cells of gills of *Cyprinus carpio communis* - SEM study. *J. Environ. Biol.* 28(3):663-667
- Joseph, B. and Raj, S.J., 2010. Effect of curacron toxicity on the total serum protein content of *Cyprinus carpio*. *Toxicol. Environ. Chem.* 92: 1889-1893
- Kunjamma, A.K.P., Philip, B., Bhanu, S.V. and Jose, J. 2008. Histopathological effects on *Oreochromis mossambicus* (Tilapia) exposed to Chlorpyrifos. *J. Environ. Res. Dev.* 2(4): 553-559
- Marutirao, G. R., 2012. Histopathological changes in the gills of *Puntius ticto* (Ham) under dimethoate toxicity. *Bioscan.* 7(3): 423-426
- Meyers, T.R. and Hendricks, J.D. 1985. Histopathology. In: (Eds., Loux, D.B., Dorfman, M.) *Fundamentals of Aquatic Toxicology: Methods and Applications*, Hemisphere USA, pp. 283-330
- Mohamed, F.A., 2001. Impacts of environmental pollution in the southern region of Lake Manzalah, Egypt, on the histological structures of the liver and intestine of *Oreochromis niloticus* and *Tilapia zillii*. *J. Egypt. Acad. Soc. Environ. Develop.*, 2: 25-42.
- Oritz, J.B., Gonzalez. D. C. M. L. and Sarasquete, C. 2003. Histopathological changes induced by London (HCH) in various organs of fishes. *Sci. Mar.* 67(1):53-61.
- Pandey, A.K., George, K.C. and Peer Mohamed, M. 1996. Histopathological alterations induced
- Parashar, R.S. and Banerjee, T.K. 2002. Toxic impact of lethal concentration of lead nitrate on the gills of air breathing catfish *Heteropneustes fossilis* (Bloch). *Vet. Arhiv.* 72(3): 167-183
- Ptashynski, M., Pedlar, Evan, R. Baron, C. and Klaver Kamp, J. 2002. Toxicology of dietary nickel in lake white fish (*Coregonus lupeaformis*). *Aquat. Toxicol.*, 58: 229-247.
- Radhaiah, V. and Jayantha Rao, K. 1992. Fenvalerate toxicity to the liver in a freshwater teleost, *Tilapia mossambica* (Peters). *Comp. Physiol. Ecol.* 17(2): 48-53.
- Rajkowska, M. and Protasowicki, M. 2011. Distribution of selected metals in bottom sediments of lakes In sko and Wiola (Poland). *Ecol. Chem. Engineer.* 18: 805-812.
- Rani, S. and Venkataramana, G. V. 2012. Effects of the organophosphorous Malathion on the branchial gills of a freshwater fish, *Glossogobius giurus* (Ham). *Int. J. Sci. Nat.* 3(2): 324-330
- Rodrigues, E.D.L., Ranzani-Paiva, M.J.T., Pacheco, F.J. and Veiga, M.I.D. 2001. Histopathologic lesions in the liver of *Prochilodus lineatus* (Pisces, Prochilodontidae) exposed to a sublethal concentration of the organophosphate insecticide Dipterex 500 (Trichlorfon). *Maringa*, 23(2): 5003-505.
- Rusyniak, D.E. and Nanagas, K.A. 2004. Organophosphate poisoning. *Semen. Neurol.* 24: 197-204
- Sakr, S.A. and Jamal Al Lail, S.M. 2005. Fenvalerate induced histopathological and histochemical changes in the liver of the cat fish *Clarias gariepinus*. *J. Applied Sci. Res.*, 1(3): 263-267.
- Santos, R. F. B., Dias, H. M. and Fujimoto, R. Y. 2012. Acute toxicity and histopathology in ornamental fish amazon blue spotted corydora (*Corydoras melanistius*) exposed to formalin. *Ann. Braz. Acad. Sci.* 84(4): 1001-1007
- Soufy, H., Soliman, M., El-Manakhy, E. and Gaafa, A. 2007. Some biochemical and pathological investigations on monosex tilapia following chronic exposure to carbofuran pesticides. *Global Veterinaria*, 1: 45-52.
- Tilak, K.S. and Veeraiah, K. 2001. Toxicity and effect of Chlorpyrifos to the freshwater fish, *Labeo rohita* (Hamilton). *Poll. Res.* 20(3):443-445
- Tilak, K.S., Veeraiah, K. and Koteswara Rao, D. 2005. Histopathological changes observed in the gill, liver, brain and kidney of the Indian major carp *Cirrhinus mrigala* (Hamilton) exposed to chlorpyrifos. *Poll. Res.* 24(1): 101-111.
- Ullah, R., Zuberi, A. and Tariq, M., Ullah, S. 2014d. Acute toxic effects of cypermethrin on hematology and morphology of liver, brain and gills of Mahseer (*Tor putitora*). *Int. J. Agri. Biol.* In press.
- Velmurugan, B., Selvanayagam, M., Cengiz, E.I., and Unlu,

- E. 2007. The effects of fenvalerate on different tissues of freshwater fish, *Cirrhinus mrigala*. J. Environ. Sci. Health Part B. 42(2): 157-163
- Venkateswara, R., 2005. Sublethal effects of an organophosphorus insecticide (RPR-II) on biochemical parameters of tilapia, *Oreochromis mossambicus*. Camp. Biochem. Physiol. Part C: Toxicol. Pharmacol. 143(4),492-498
- Vinodhini, R. and Narayanan, M. 2008. Bioaccumulation of heavy metals in organs of fresh water fish *Cyprinus carpio* (Common Carp). Int. J. Environ. Sci. Tech. 5(2): 179-182.

**How to cite this article:**

Muttappa K *et al.*, Chlorpyrifos Induced Histological Changes In The Liver Of Tilapia (*Oreochromis Mossambicus*). *International Journal of Recent Scientific Research Vol. 6, Issue, 8, pp.5819-5823, August, 2015*

\*\*\*\*\*