



RESEARCH ARTICLE

FUNCTIONAL OUTCOME OF FRACTURE TIBIA USING DCP IMPLANT WITH MIPO METHOD AND TECHNOLOGY

¹Vijay Mahantesh Sunkad*, ²Vijaya Mahanth Prasad.K, ³Jyothi Gopal and ⁴Chethana. K.V

^{1,2} Senior Resident, Department of Orthopedics

³Senior Resident, Department of Anesthesia

⁴Department of Community Medicine

ARTICLE INFO

Article History:

Received 12th, October, 2014

Received in revised form 22th, October, 2014

Accepted 15th, November, 2014

Published online 28th, November, 2014

Key words:

Minimal Invasive Plate Osteosynthesis (MIPO)
Biological Osteosynthesis (BO), Intramedullar
Nailing (IMN)

ABSTRACT

Background: The tibia is the most commonly fractured bone of all the long bones of the body. Due to its poor blood supply and less soft tissue coverage there is an increased incidence of delayed union and non union. Biological plating techniques are those in which blood supply to the fractured fragments is maximally preserved. **Aims and Objectives:** 1. To access the over all final functional results of patient and return to normal activity. 2. To evaluate the Union rate and the average time taken for fracture union with MIPPO. **Methodology:** Study was conducted between December 2009 to November 2012. 168 adult patients of either sex with diaphyseal fracture of tibia (upper 2/3rd shaft) were the study group (Males 112 Females 56). Open fractures were excluded. **Results:** 168 cases of fracture of diaphysis of tibia were managed by dynamic compression plate using MIPO technique. Majority of the subjects were males 84% and the rest 16% were females. The study revealed that most of tibial diaphyseal fractures (68%) occurred in young adults ie less than 30 years of age. 59 cases were tibial shaft fractures, 48 were mid 1/3, 44 were distal 1/3, 9 were segmental, 8 were isolated tibia fractures. The average duration of union of the fracture in mid shaft tibia was 8-12 weeks, upper 2/3rd and lower 1/3rd junction was 8-10 weeks, lower 2/3rd and upper 1/3rd junction is 8-10 weeks, segmental 14-16 weeks, isolated tibia 8-9 weeks.

© Copy Right, IJRSR, 2014, Academic Journals. All rights reserved.

INTRODUCTION

The tibia is the most commonly fractured bone of all the long bones of the body. No fracture in the body arouses more controversy regarding treatment than tibial fracture. Due to their frequency, topography, mode of injury and sometimes type of treatment, they have become source of temporary or permanent disability. ⁽¹⁾ In recent years, Minimally invasive plate osteosynthesis (MIPO), a new technology developed under the guidance of BO rules is ⁽²⁾ has become widely accepted for treatment of periarticular fractures, Metaphyseal fractures, and certain diaphyseal fractures where intramedullary nailing is not indicated. ⁽³⁾ there has been evidence showing superiority of biological fixation over a stable mechanical fixation. ⁽⁴⁾ the use of MIPO prevents

1. Large surgical approach
2. Extensive soft tissue stripping
3. Disruption of periosteal blood supply
4. Nerve palsies

More over MIPO shortened the union time after surgery and the period of rehabilitation. Thus , MIPO helps people back to work as soon as possible. ⁽⁵⁾

MIPO is now widely used in long bone fractures, mainly in humerus, tibia and femur. Operative procedures and characteristics are distinctive in different fracture sites.

Fractures of the tibia still pose a challenge to the orthopaedic surgeon due to certain peculiarities like; tibia is a

subcutaneous bone so more chances of open type of fracture, greater tendency of displacement of tibial fractures and increased chances of post-op infection. Due to its poor blood supply and less soft tissue coverage there is an increased incidence of delayed union and non union. Biological plating techniques are those in which blood supply to the fractured fragments is maximally preserved. The objective of biologic fixation is to assist physiological process of bone healing wisely and optimally with minimal amount of operative intervention. Stress is laid on maintaining a precarious balance between devascularisation and mechanical perfection. ⁽⁶⁾

Biological fixation principles can be summarized as

Repositioning and realigning by manipulation at a distance to fracture site, preserving soft tissues (Indirect reduction techniques).

- Leaving comminuted fragments out of the mechanical construct, while preserving their blood supply.
- Using low elastic modulus, biocompatible materials.
- Limited operative exposure.

Minimally invasive plate osteosynthesis (MIPPO) is one such method in which percutaneous inserted plate is fixed at a distance proximal and distal to the fracture site through minimal exposure.

Advantages cited for MIPPO

- Simpler technique, easy to master.
- No need of additional expensive instrumentation.

* Corresponding author: **Vijay Mahantesh Sunkad**
Department of Senior Resident, Department of Orthopedics

- Improved rates of union.
- Decreased infection rate.
- Decreased need for bone grafting.
- Ideal technique for dealing with multiply injured patient.
- Early mobilisation of extremity possible.

Aims and Objectives.

- To access the over all final functional results of patient and return to normal activity.
- To evaluate the Union rate and the average time taken for fracture union with MIPPO..

METHODOLOGY

Study was conducted between December 2009 to November 2012. 168 adult patients of either sex with diaphyseal fracture of tibia (upper 2/3rd shaft) were the study group (Males 112 Females 56). Open fractures were excluded.

All cases were assessed initially in emergency room and they were provided with first aid and splintage in order to make the patient comfortable and reduce the chances of displacement of fracture fragments and thus avoiding further complications. Baseline investigations were done so as to access the fitness of patient for anaesthesia.

Routine blood investigations, CT, Serum urea, Serum creatinine, Serum electrolytes, Urine (R/e), ECG and Radiograph of local part including knee and ankle joint (AP and Lateral view),MRI chest X- ray were taken.

Table 1 Distribution of subjects according to Age Category

Age Group (years)	Number	Percentage (%)
< 30 years	114	68%
30-50 years	20	12%
>50 years	34	20%
Total	168	100%

Table 2 Table showing average duration of union and complication in the subjects

Area Involved	No. of subject	Avg. duration of Union	Complications
Tibia Shaft (Mid)	59	8-12wks	2 non union and 1 Infected Nonunion
Upper 2/3 Lower 1/3 Jn	44	8-10wks	1 Nonunion 1 Infected Nonunion
Lower 2/3 Upper 1/3 Jn	48	10-14wks	2 Nonunion
Segmental	9	14-16wks	--
Isolated Tibia	8	8-9wks	1 Nonunion
Total	168	9.9wks	8 Nonunion

Inclusion Criteria: Transverse fracture, Oblique fracture, Comminuted fracture, Spiral fracture.

Exclusion Criteria

1. Compound fractures with significant soft tissue damage.
2. Pathological fractures.
3. Intraarticular fractures.
4. Old fractures ie more than 2 weeks old.
5. Fractures with compartment syndrome or impaired circulation.

Technique

After the selection of the cases for surgery, patients were prepared for elective surgery to be conducted in main operation theatre. All patients received pre-op antibiotics. Limb was anaesthetised with the help of spinal, epidural or general anaesthesia. Tourniquet was applied around the thigh over adequate cotton padding to achieve clear/ bloodless field during surgery. Maximum time for tourniquet application was no more than 45 min to 1 hr.

RESULTS

168 cases of fracture of diaphysis of tibia were managed by dynamic compression plate using MIPO technique in this series over a period of three years. About 28% of the patients in his study have been found to be associated with other injuries signifying that fracture tibia is usually involved in Polytrauma patients. 52% of the cases have been operated within a period of 6-10 day's from injury in our study. Most of the patients were discharged on removal of the sutures on 14th post op day.

This study revealed that most of tibial diaphyseal fractures (68%) occurred in young adults ie less than 30 years of age.

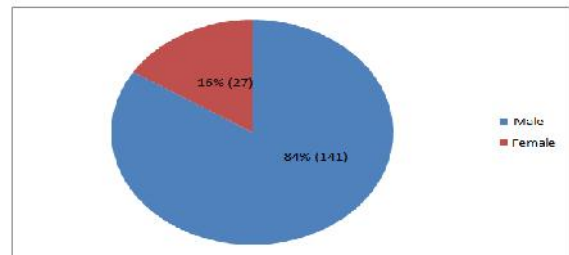


Fig 1 Distribution of Subjects according to Gender

Majority of the subjects were males 84% and the rest 16% were females.

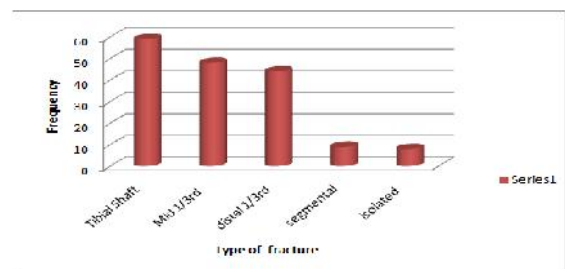


Fig 2 Distribution of subjects according to site of the Fracture

59 cases were tibial shaft fractures, 48 were mid 1/3, 44 were distal 1/3, 9 were segmental, 8 were isolated tibia fractures

The average duration of union of the fracture in mid shaft tibia was 8-12 weeks, upper 2/3rd and lower 1/3rd junction was 8-10 weeks, lower 2/3rd and upper 1/3rd junction is 8-10 weeks, segmental 14-16 weeks, isolated tibia 8-9 weeks.

The duration of radiation exposure and the time taken to perform the surgical procedure reduced significantly as we expertised in the procedure, as indicated in the above figure.

DISCUSSION

It is demonstrated that wound complications of MIPO, such as wound infection and implant impingement, in shaft of tibia is common in our study, contrast to other studies saying distal tibia are more common. (7) A study reveals that IMN should be the first method of treatment for the internal fixation for tibia fractures. (8) However when the fracture line is less than 5cm

proximal to the ankle joint IMN is not applicable. ⁽⁹⁾ MIPO technique can be an alternative method for those cases IMN is

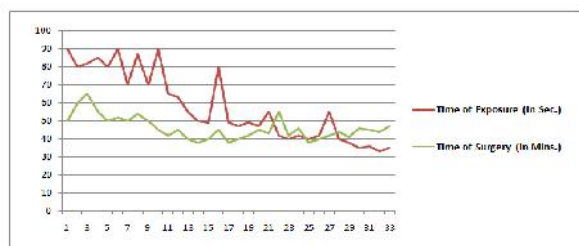


Fig 3 Time of C Arm exposure (brown colour) and duration of surgery (green colour)

not available. ⁽⁸⁾ Various treatment methods have been used for proximal Biological fixation is based on other minimally invasive methods of fixation such as intramedullary nailing. These techniques are newer and technically demanding. Indirect reduction techniques are developed to reduce soft tissue damage at the fracture site and to improve the rate of fracture healing. Thus the good results in this method can be explained by a combination of rapid fracture consolidation due to preserved vascularity and a greatest resistance of the plate to fatigue, since the stress is distributed over a longer length of plate. Our study has focussed on the above treatment modality with use of Dynamic compression plate. Union rate in our study was better than Vander Larsen series (1979) attributed to principles of biological fixation..

CONCLUSION

On the basis of the findings in the study it can be concluded that MIPO is a good choice in treatment of long bone fractures in lower extremities. It can be used either independently or along with external fixation either in closed or open fractures. The application of dynamic compression plate using MIPPO technique does not compromise with the periosteal blood supply thereby causing less interference with the fracture haematoma and the fracture healing.

- There is less incidence of infection due to limited exposure.
- There is no need of any specialised instrumentation and the method is less time consuming and cost effective.
- There are few incidences of delayed and non union.
- This technique can be used in fractures where locked nailing can't be done like vertical slit and markedly comminuted fractures, narrow or very wide medullary canals, fractures with metaphyseal extension and osteoporotic fractures and bad skin condition at the entry portal of I/M nail.
- There is decreased need for bone grafting.
- Plate induced osteoporosis is less frequently seen with dynamic compression plate so there are less chances of refracture after plate removal

- There is no chance of vascular complication by carefully inserting the plate sub muscularly through limited incision.
- Soft tissue complications knee and ankle stiffness are avoided.
- Few cases complained of palpable hardware which can be minimised by using low profile titanium plate.

Hence the procedure is reliable approach towards the management of tibial diaphyseal fractures with proper indications.

References

1. AO manual of orthopaedics: 3rd edition: Reprint 1999; 118-122.
2. B. Livani, W. Belangero, K. Andrade, G. Zuiani and R. Pratali, "Is MIPO in humeral shaft fractures really safe? Post operative ultrasonographic evaluation" *International Orthopedics*, Vol 33, No 6, 2009, pp. 1719-1723. doi:10.1007/s00264-008-0616-x
3. C.Kayali, H. Agus, A. Eren and S. Ozluk, " How Should open tibia fractures be treated? A retrospective comparative study between intramedullary nailing and biologic plating," *Turkish journal of trauma and emergency surgery*, Vol. 15, No. 3, 2009, pp. 243-248.
4. Cheng W, Li Y, Manyi W, "Comparision Study of two surgical options for distal tibia fracture- Minimally invasive Plate osteosynthesis Vs Open reduction and internal fixation," *International orthopedics*, Vol.35, No.5, 2011, pp. 737-742. doi:10.1007/s00264-010-1052-2
5. F. Baumgaertel, M. Buhl and B. A. Rahn, "Fracutre healing in biological plate Osteosynthesis" *injury*, Vol 29, no. S3, 1998, pp C3-C6. doi:10.1016/S0020-1383(98)95002-1
6. Krettek C: Foreword, "Concepts of minimum invasive plate osteosynthesis", *Injury*, Volume 28 No. S1, 1997, pp. A1-A2. doi:10.1016/S0020-1383(97)90108-X
7. M Tantray, G Kuchey, A Wani, D Habib, S Sharma, M Habib. A Clinical Study For Management Of Tibial Diaphyseal Fractures In Adults With Locking Compression Plate Using Mippo Technique. *The Internet Journal of Orthopedic Surgery*. 2010 Volume 18 Number2.
8. T. Apivatthakakul, O. Arpornchayanon, S. Bavornratanavech, "Minimally invasive plate osteosynthesis (MIPO) of the humeral shaft fracture. Is it possible? A Cadaveric study and preliminary report," *Injury*, Vol. 36 No. 4, 2005, pp 530-538. doi:10.1016/j.injury.2004.05.036
9. T.W. Lau, F. Leung, C.F. Chan and S.P. Chow, "Wound complication of minimally invasive plate osteosynthesis in distal tibia fractures," *International orthopedics*, Vol. 32, No. 5, 2008, pp. 697-703. doi:10.1007/s00264-007-0384-z
