



ISSN: 0976-3031

Available Online at <http://www.recentscientific.com>

International Journal of Recent Scientific Research  
Vol. 7, Issue, 10, pp. 13730-13734, October, 2016

**International Journal of  
Recent Scientific  
Research**

## Case Report

### FULL MOUTH REHABILITATION WITH DENTAL IMPLANTS IN PATIENT WITH PARTIAL EDENTULOUS CONDITION AND GENERALIZED CHRONIC PERIODONTITIS: A CASE REPORT

**Chandrashekhar R Shanagonda<sup>1</sup>, Jyoti P Tembhurne<sup>2</sup>, Manish Ashtankar<sup>3</sup>, Sandeep Pimpale<sup>4</sup> and Tanay U Gunjekar<sup>5</sup>**

<sup>1,2</sup>Department of Prosthetic Dentistry Government Dental College & Hospital, Mumbai

<sup>3,4</sup>Department of Periodontics and Implantology, Nair Hospital & Dental College, Mumbai

<sup>5</sup>Department of Periodontics Government Dental College & Hospital, Mumbai

#### ARTICLE INFO

##### Article History:

Received 18<sup>th</sup> July, 2016

Received in revised form 10<sup>th</sup> August, 2016

Accepted 06<sup>th</sup> September, 2016

Published online 28<sup>th</sup> October, 2016

##### Key Words:

Implants, Osteotomy Site, Fixed Prosthesis, Open Tray Impression Coping

#### ABSTRACT

Replacement of teeth should be done to restore the functions like mastication, phonetics, and esthetics. In the present day, many treatment options are available, among them, treatment with dental implants had evolved as a major choice. Among all types of implants, endosseous implants had gained more importance than any other type of implants. The case report describes a patient who had chronic periodontitis with several missing maxillary and mandibular teeth. The patient underwent (1) deep scaling, root planning with systemic dosage of antibiotics (2) extraction of teeth with a hopeless prognosis, and (3) full mouth rehabilitation to restore missing and extracted tooth structure with dental implants.

**Copyright © Chandrashekhar R Shanagonda et al., 2016**, this is an open-access article distributed under the terms of the Creative Commons Attribution License, which permits unrestricted use, distribution and reproduction in any medium, provided the original work is properly cited.

## INTRODUCTION

Aggressive periodontitis as defined by the international workshop for classification of periodontal diseases and conditions is “a multifactorial, severe and rapidly progressive form of periodontitis, which primarily but not exclusively affects young individuals.”<sup>1</sup> Primary treatment modalities for periodontitis are deep scaling, root planning and flap surgeries along with systemic dosage of antibiotics will be more effective. Other treatment modalities include extraction of teeth with hopeless prognosis and restoration of extracted teeth with a removable or fixed prosthesis. Crown & bridge, dental implants are choice for fixed prosthesis to restore patient to normal function and health. Dental implants have become an integral part of prosthetic rehabilitation. Implant therapy for periodontally compromised patients has been documented by various studies. Schou has performed a review on “Outcome of implant therapy in patients with tooth loss due to periodontitis” in which human studies carried out from 1986 to 2006 were reviewed. This review concluded that the survival rate of implants and superstructures of individuals with periodontitis was not significantly different than individuals who did not have periodontitis prior to tooth loss.<sup>2</sup>

### Case Report

A 38-year-old male patient came with the chief complaint of replacement of missing teeth. On intraoral examination, single unit acrylic provisional prosthesis was present in upper arch, clinical examination done after removing provisional prosthesis. Following teeth were present in patient: 13, 15, 17, 23, 25, 27, 31, 33, 35, 37, 41, 42, 43, 44, 45 & 47 (Figure 1, 2 & 3). Following teeth showed Grade III mobility: 31, 33, 35, 41, 42 & 44. Patient did not have a history of any habits like smoking or pan chewing. Radiographic examination showed severe bone loss around 31, 33, 35, 41, 42 & 44.

After a thorough analysis, a decision was made to proceed with periodontal treatment including deep scaling, root planning combined with antibiotic therapy and then extraction of teeth with hopeless prognosis and followed by prosthetic restoration for the missing teeth. The patient was explained about advantages and disadvantages of dental implant treatment. Patient was expressed his desire for fixed prosthetic treatment with dental implants.

### Clinical procedure

Patient appointed for deep scaling and root planning after completion of premedication with antibiotics for three days.

\*Corresponding author: **Chandrashekhar R Shanagonda**

Department of Prosthetic Dentistry Government Dental College & Hospital, Mumbai

After anaesthetizing with 2% lignocaine, deep scaling was carried out with an ultrasonic scaler and root planning done with elevating full thickness periosteal flap. Curettage was done with surgical curette and root planning also done. Granulation tissue was removed and surgical site was irrigated with betadine and normal saline. After completion of scaling and root planning procedure flaps were approximated in both arches and sutured. Antibiotics and analgesics prescribed and recalled after one week for suture removal. Patient recalled every two weeks for evaluation of healing of soft tissue and evaluation of plaque accumulation. After six months, patient was evaluated and decided to extract 31, 33, 34, 41, 42 and 44 for further treatment plan.

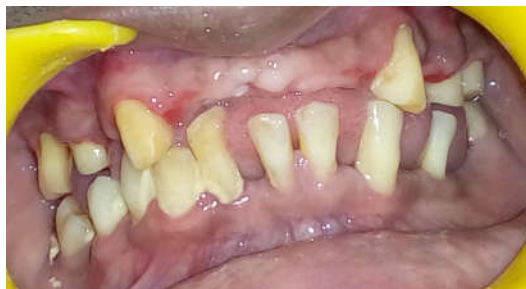

Figure 1 Preoperative view

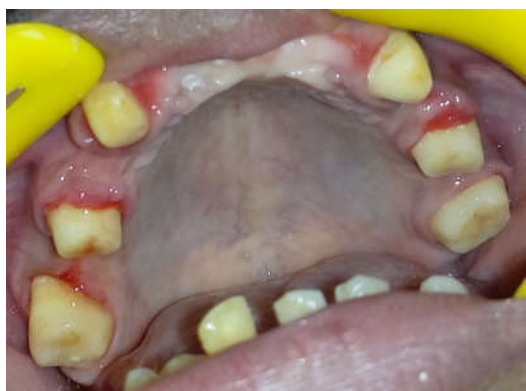

Figure 2 Intraoral view showing upper teeth after removal of provisional prosthesis

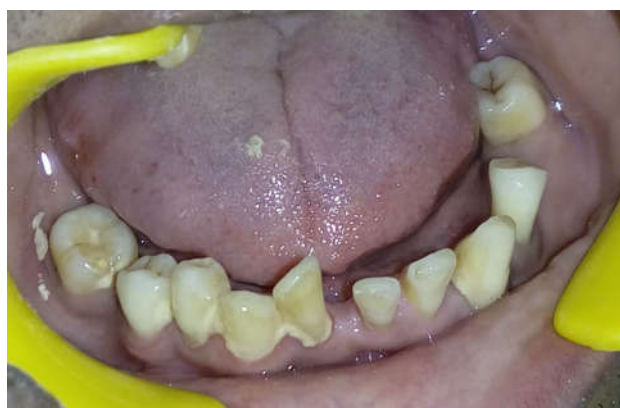

Figure 3 Intraoral view showing lower teeth

After Cone Beam Computed Tomography (CBCT) evaluation of upper and lower arch, required dimensions of dental implants (Adin Implant System) were planned in 14, 24, 31, 33, 34, 36, 42, 44 and 46 region. Maxillary and mandibular alginate impressions were made. Diagnostic casts were mounted in semi-adjustable articulator using face bow transfer

and interocclusal records. Teeth were reduced till the cervical level to arrange the artificial teeth. The completed teeth arrangement was duplicated in clear acrylic as a surgical guide. Openings were made on the cingulum of anterior teeth and occlusal surface of posteriors to identify osteotomy points during the surgery.

The two-stage surgical protocol was planned and patient was asked to have antibiotics and analgesics one hour prior to surgery. The surgical procedure was carried out under local anaesthesia in a sterile condition. Upper bilateral first premolar area was infiltrated buccally and palatally with 2% Lignocaine HCl (1:200000 Adrenaline) and full thickness mucoperiosteal flap was elevated, osteotomy sites preparation were carried out through surgical template in place, dental implants were placed in osteotomy sites with more than 35Ncm torque. Flaps were approximated and sutured with 3-0 black silk (Mersilk, 3-0, Reverse Cutting Needle). Post-operative IOPA radiograph was taken for evaluation of the position of implant.

Bilateral inferior alveolar nerve block was given with 2% Lignocaine HCl (1:200000 Adrenaline). After achieving sufficient anaesthesia effect, crestal and sulcular incision were given and full thickness mucoperiosteal flap was elevated from 37 to 47 region. 31, 33, 35, 41, 42, 44 were extracted with minimal bone expansion. All extraction sites were then debrided of any granulation tissue with curette and surgical template placed. Osteotomies were performed through surgical template with twist drills in sequence with copious saline irrigation. Once adequate osteotomy sites preparation achieved, dental implants with planned dimensions were placed in osteotomy sites with more than 40Ncm torque. Cover screws placed with hex driver. Any gaps between implants and the existing sockets were grafted with a mixture of demineralised and mineralized allograft (Demineralised Freeze Dried Bone Allograft & Mineralised Freeze Dried Bone Allograft, Tata Memorial Hospital, Mumbai). In cases like this, the combination of immediate placement and grafting give the best potential outcome. After grafting, buccal and lingual flaps approximated and sutured.

Post-operative IOPA radiograph was taken for evaluation of position of implants. Patient was given routine post-surgical instructions and medication. Patient was examined after 07 days during which sutures removed. Routine postoperative examinations were completed at 4 weeks, and at 3 months.

After 6 months, radiographic and clinical examination revealed successful osseo-integration and stable crestal bone height. Second stage implant surgery carried out to place healing abutments. After two weeks of healing abutments placement patient was appointed for final impression. On the day of appointment for final impression, provisional prosthesis were removed, temporary cement cleaned, tooth preparation modified with remaining natural teeth and open tray impression copings placed in 14, 24, 31, 33, 34, 36, 42, 44 and 46 implant regions and tightened with hex driver. All impression copings in a lower arch in 31, 33, 34, 36 and 42 regions are splinted with dental floss and pattern resin. After complete setting of pattern resin, it was cut through a middle portion of the pattern resin and again pattern resin was added in same area to decrease polymerization shrinkage (Figure 4).

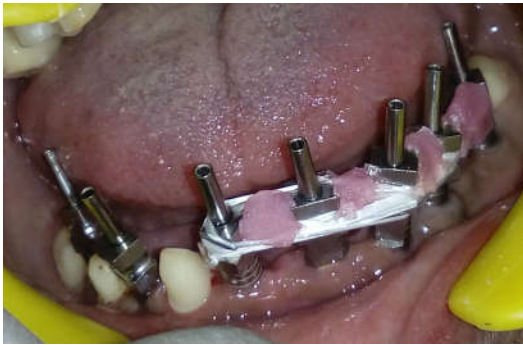


Figure 4 Impression copings placed in lower arch and joined with pattern resin

Upper and the lower final impression made with polyvinyl siloxane impression material (Aquasil Monophase, Dentsply) with modified open tray impression technique (Figure 5 & 6).

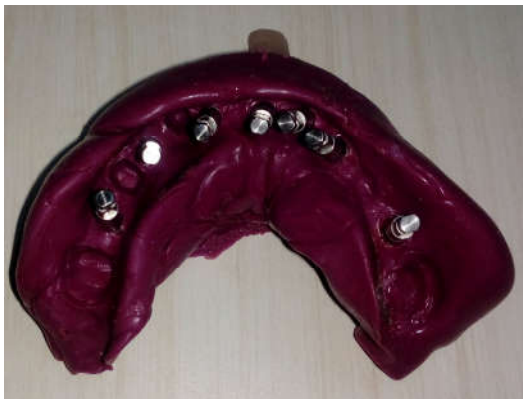

Figure 5 Lower final addition silicone impression

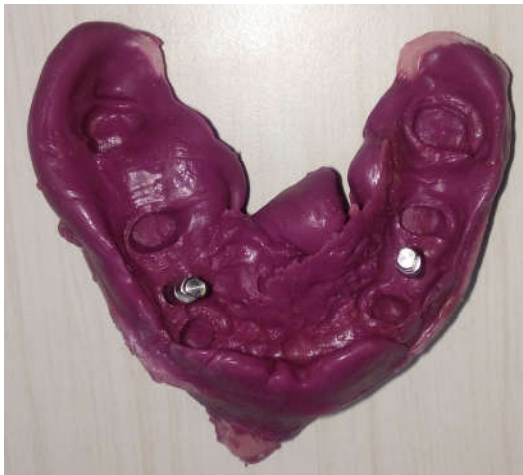

Figure 6 upper final addition silicone impression

Plastic abutments placed into implants in 31,33,34,36 and 42 region, titanium abutments placed in 14, 24, 44 and 46 regions and verified their fit with radiographs. Master casts were obtained and jig trial was prepared on the master cast with non-hex plastic abutments and pattern resin in lower left first molar region to lower right lateral region. Jig trial was verified intra-orally by its passive fit into implants (Figure 7). Upper and lower screw retained occlusal rims were prepared on master casts. Maxillo-mandibular relations were recorded, transferred to Hanau semi adjustable articulator and try-in of waxed up trial with acrylic teeth was verified for articulation, speech and aesthetics (Figure 8).

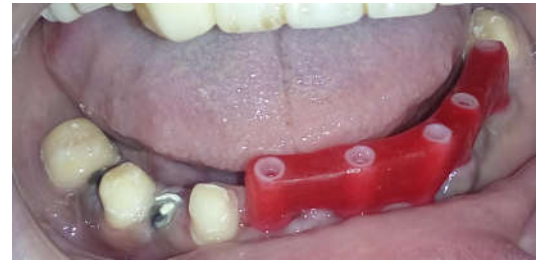


Figure 7 Jig trial taken

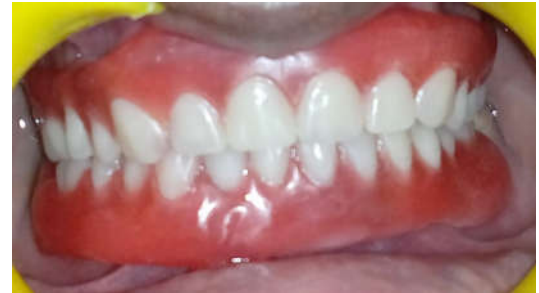

Figure 8 Waxed up trial

The case was then sent back to the lab for casting for FPD as follows (Figure 9a,9b & 9c):

1. Six unit bridge in upper right canine to upper left canine,
2. Three unit FPD in upper right second premolar to upper right second molar,
3. Three unit upper left second premolar to upper left second molar,
4. Single unit crowns with tooth number: 37, 43, 45 & 47,
5. Screw retained implant prosthesis in lower right first molar to lower left lateral incisor,
6. Cement-retained implant prosthesis in 14, 24, 44 & 46 regions.

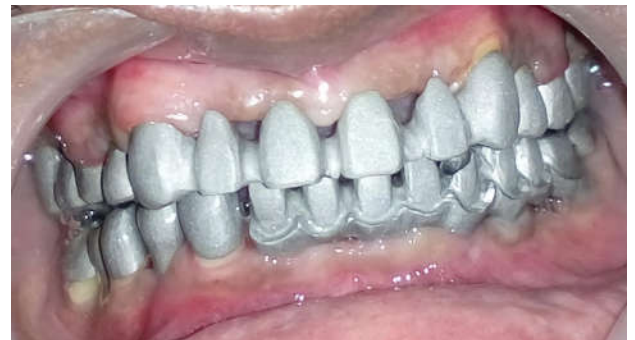

Figure 9a- Metal trial

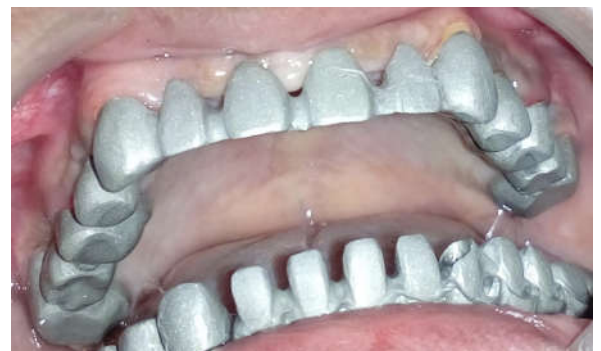

Figure 9b-metal trial

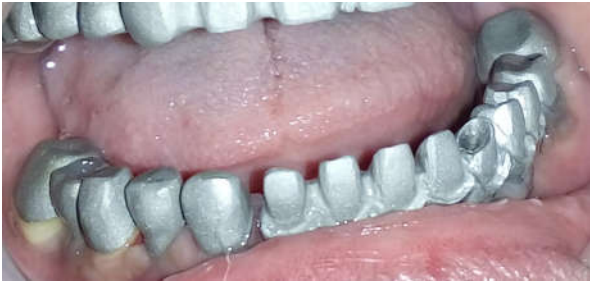

Figure 9c Metal trial

After metal trial, the case was again sent back to the lab for the final prosthesis (Figure 10a & 10b).

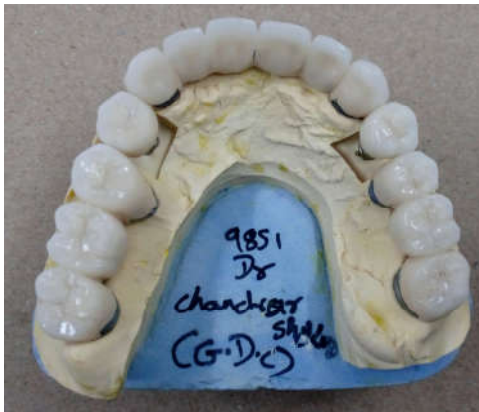


Figure 10 a- Final prosthesis on master cast

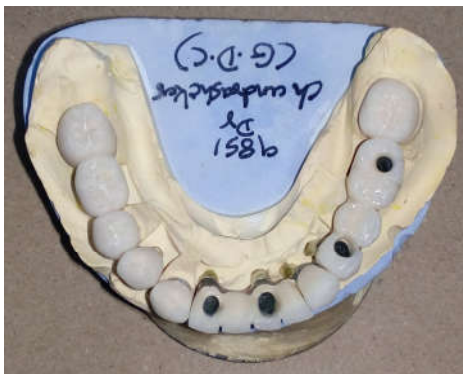


Figure 10b- Final prosthesis on master cast

The final prosthesis was delivered. Occlusal adjustment was carried out using articulation paper and a fine diamond bur. The occlusal surfaces were then polished with ceramic polishing discs (Shofu, Ceramic Finishing, and Polishing Kit). The abutment screws were all retightened to 25Ncm torque and the access holes filled with sterile cotton pellet and blocked with flowable composite and polished (Figure 11 to Figure 15).

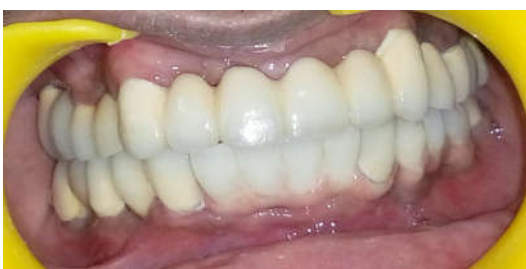

Figure 11 Intraoral view of final prosthesis

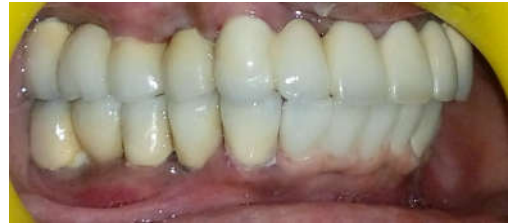

Figure 12 Postoperative right lateral view

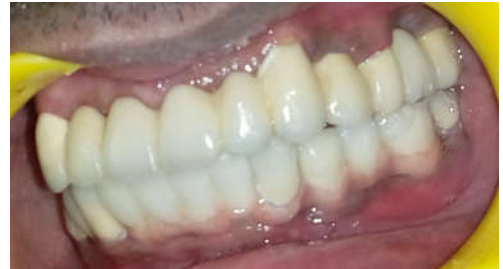

Figure 13 Postoperative left lateral view

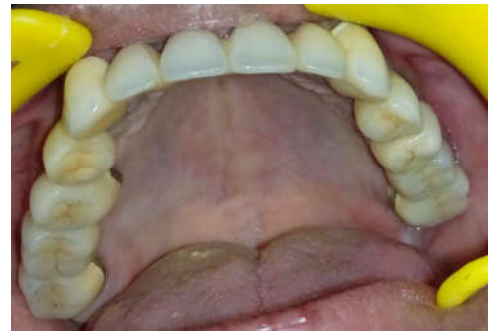

Figure 14 Upper occlusal view

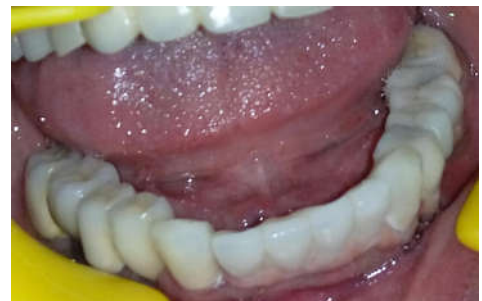

Figure 15 Lower occlusal view

A postoperative radiograph was taken to assure all cement was removed and restorations were completely seated. The patient was followed up at one-week post-delivery and then at a 6-month recall appointment. Follow-up visits were more frequent in this case due to the case of chronic periodontitis.

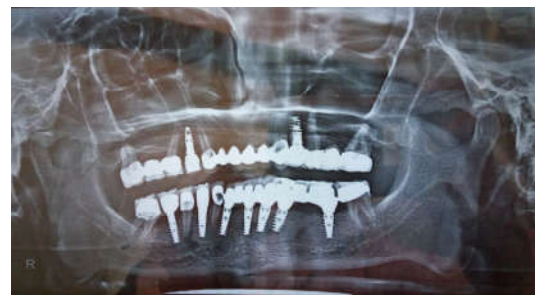

Figure 16 Orthopantomogram (OPG)

Oral hygiene measures were reinforced and their hygiene status was evaluated at every recall visit. Orthopantomogram taken after one year follow-up showing no crestal bone loss (Figure16).

## DISCUSSION

Studies have shown that dental implants show promising success rate in patients with periodontal diseases.<sup>3</sup> Treatment for missing teeth with generalized chronic periodontitis starts with the removal of the cause for periodontitis in existing dentition combined with antibiotic therapy. Peri-implantitis is most common complication with dental implants placed in chronic periodontitis if oral hygiene would be compromised.

A critical review of dental implant prognosis in periodontally compromised with partially edentulous space was performed by Karaussis in articles that were published until 2006. This study shows that there was no statistically significant differences in both short-term and long-term implant survival exist between patients with a history of chronic periodontitis and periodontally healthy individuals.<sup>4</sup> Prosthetic driven surgical placement of implants with canine guidance occlusal system given healthy implant supported and tooth supported dentition in failing natural dentition. In the maintenance phase, implant evaluation done every 3 monthly to calculate risk of plaque. Primary stability of implants can be obtained by choosing appropriate implant width and length and utilizing remaining cortical bone.<sup>5,6</sup>

An open tray impression technique was used in this case with joining impression copings with pattern resin to get accurate impression. It was found that for situations in which there were 4 or more implants, more studies showed more accurate impressions with the pick-up technique than the transfer technique.<sup>7</sup> The splint technique for an implant impression was introduced along with the development of a metal-acrylic resin implant fixed complete denture for an edentulous jaw.<sup>8</sup> The underlying principle was to connect all the impression copings together using a rigid material to prevent individual coping movement during the impression- making procedure. Splinting has been an important. Even though there was no consistent result for higher accuracy with one technique as opposed to the other, splint or nonsplint, more studies reported more accurate implant impressions with the splint technique than with the nonsplint technique.<sup>9</sup> Standard diagnostic criteria were used for the assessment of implant failures, which included clinical signs of infection, clinical mobility and radiographic signs of failure.<sup>10</sup> This case report is to explain rehabilitation of partial edentulous patient with chronic periodontitis with dental implants with canine guided occlusion, eliminating the periodontitis.

## CONCLUSION

Many cases documented that edentulous condition with chronic periodontitis can be treated with dental implants with good success rate to normal condition.

In this case report with one year follow up, no implant failure occurred. During recall visits plaque accumulation, peri-implant tissue biological condition, occlusal contacts, canine guidance evaluated. And radiographs were taken to evaluate bone implant interface, crestal bone height and periapical pathology with remaining natural dentition.

However, more follow-up period required in this type of study to evaluate dental treatment modality in partial edentulous condition with chronic periodontitis. This case demonstrates the type of dentistry that can change lives. It also shows how we can meet the needs of patients can be satisfied by providing predictable, long-lasting rehabilitation in less time than ever before possible. In present case report, the patient was fully satisfied with the treatment outcome compared to his previous condition.

## References

1. Armitage GC. Development of a classification system for periodontal diseases and conditions. *Ann Periodontol.* 1999; 4:1–6.
2. Schou S. Implant treatment in periodontitis-susceptible patients: A systematic review. *J Oral Rehabil.* 2008; 35(Suppl 1):9–22.
3. García-Bellosta S, Bravo M, Subirá C, Echeverría JJ. Retrospective study of the long-term survival of 980 implants placed in a periodontal practice. *Int J Oral Maxillofac Implants.* 2010; 25:613–9.
4. Karoussis IK, Kotsovilis S, Fourmouis I. A comprehensive and critical review of dental implant prognosis in periodontally compromised partially edentulous patients. *Clin Oral Implants Res.* 2007; 18:669–79.
5. Esposito M *et al.* Worthington HV. The effectiveness of immediate, early, and conventional loading of dental implants: a cochrane systematic review of randomized controlled clinical trials. *Int J Oral Maxillofac Implants* 2007; 22:893-904.
6. Greenstein G *et al.* Clinical recommendations for avoiding and managing surgical complications associated with implant dentistry: a review. *J Periodontol* 2008; 79:1317-29.
7. Heeje Lee *et al.* The accuracy of implant impressions: A systematic review. *J Prosthet Dent* 2008; 100:285-291.
8. Brånemark P-I, Zarb GA, Albrektsson T. Tissue-integrated prostheses. 1st ed. Chicago: Quintessence; 1985. p. 253.
9. Humphries RM, Yaman P, Bloem TJ. The accuracy of implant master casts constructed from transfer impressions. *Int J Oral Maxillofac Implants* 1990; 5:331-6.
10. Sakka S, Coulthard P. Implant failure: Etiology and complications. *Med Oral Patol Oral Cir Bucal.* 2011; 16:e42–4.

\*\*\*\*\*

### How to cite this article:

Chandrashekhar R Shanagonda.2016, Full Mouth Rehabilitation with Dental Implants in Patient With Partial Edentulous Condition And Generalized Chronic Periodontitis: A Case Report. *Int J Recent Sci Res.* 7(10), pp. 13730-13734.