



ISSN: 0976-3031

Available Online at <http://www.recentscientific.com>

CODEN: IJRSFP (USA)

International Journal of Recent Scientific Research  
Vol. 8, Issue, 12, pp. 22118-22123, December, 2017

**International Journal of  
Recent Scientific  
Research**

DOI: 10.24327/IJRSR

## Research Article

### “A STUDY ON COMPARISON OF FIXATION OF MANDIBULAR ANGLE FRACTURES USING SINGLE MINIPLATE VERSUS CURVED ANGLE RECTANGULAR STRUT PLATE”. A PROSPECTIVE RANDOMISED CLINICAL STUDY

Shajah Hussain Sheikh<sup>1</sup>, Ajaz Ahmad Shah<sup>2</sup>, Sanjay Bhagat<sup>3</sup> and Shaista Rehman<sup>4</sup>

<sup>1,3</sup>Indira Gandhi Government Dental College Jammu

<sup>2</sup>Govt. Dental College Srinagar

<sup>4</sup>Private Practitioner

DOI: <http://dx.doi.org/10.24327/ijrsr.2017.0812.1204>

#### ARTICLE INFO

##### Article History:

Received 05<sup>th</sup> September, 2017

Received in revised form 21<sup>st</sup>

October, 2017

Accepted 06<sup>th</sup> November, 2017

Published online 28<sup>th</sup> December, 2017

##### Key Words:

Rectangular strut miniplates, conventional 2.0-mm miniplates, mandible angle fracture.

#### ABSTRACT

**Aim:** To compare and evaluate the treatment outcome and postoperative complications in mandibular angle fractures using single miniplate versus curved angle strut plates.

**Materials and Methods:** This study consisted of a sample of 20 patients divided randomly but equally (single-blind control trial study) into two groups. Each group contains 10 patients. Group I was treated with open reduction and internal fixation using curved angle rectangular strut plate. Group II was treated using single 2-mm miniplates.

**Statistical Analysis:** Chi-square test.

**Results:** The results of this study suggested that there is no statistically significant difference in terms of infection, occlusal discrepancy, and union. The mean duration of rectangular plating in our study was 83.9± SD 27.299 minutes while as in single miniplate it was 47.6± SD 6.552 minutes with p value less than 0.001 which is statistically highly significant. It proves that single miniplate can be accomplished quicker than rectangular plating. Swelling increased after 2<sup>nd</sup> day of procedure and then after decreased upto 7<sup>th</sup> day of the procedure in each group. With statistically insignificant difference in both the groups. Visual analogue score increased after 2<sup>nd</sup> day of procedure and then after decreased upto 7<sup>th</sup> day of the procedure in each group with statistically insignificant difference in both the groups.

Occlusion at first week, 6 weeks, 3<sup>rd</sup> month and at 6 months were compared and it is found statistically insignificant with p value of 1. Paresthesia at first week, 6 weeks, 3<sup>rd</sup> month and at 6 months were compared and it is found statistically insignificant with p value of 1. Post-operative infection at first week, 6 weeks, 3<sup>rd</sup> month and at 6 months were compared and it is found statistically insignificant with p value of 1. In both the groups none of the patient developed wound dehiscence. Radiographic evaluations for reductions and fixation was confirmed at 1st week which was satisfactory in all patients in both the groups. Radiographic evaluation for union or non-union was confirmed at 20<sup>th</sup> week after the procedure in both the groups and it was found that there is statistically insignificant difference. In both the groups all patients return to their normal activity like speech, mastication, social interaction in 10 – 14 days with no statistically difference.

**Conclusion:** Till now no philosophy of treatment of mandibular fractures has proved superior over schampys except in cases of comminution defect or atrophic mandible.

Copyright © Shajah Hussain Sheikh, et al 2017, this is an open-access article distributed under the terms of the Creative Commons Attribution License, which permits unrestricted use, distribution and reproduction in any medium, provided the original work is properly cited.

#### INTRODUCTION

Despite many advances in internal fixation, angle fracture remains among the most difficult and unpredictable fracture to treat compared to those of other areas of the mandible. Large number of studies on mandibular angle fracture treatment attests to the fact that no single approach has been shown to be ideal, and that treatment of mandibular angle fractures remains

conceptually controversial, with a bothersome complication rate. During the last decade significant attention has been paid on variety of plate fixations for mandibular angle fractures<sup>1-12</sup>. Fixation using mini plates has been shown to simplify surgery and reduce surgical morbidity, but failed to surpass the predictability of rigid fixation. Although there have been number of studies on linear and curvilinear plates for

\*Corresponding author: Shajah Hussain Sheikh  
Indira Gandhi Government Dental College Jammu

mandibular fixation, only a few reports on the use of low profile 3-dimensional strut or mesh plates are reported in the literature<sup>1-6</sup>. In fact majority of studies on Rectangular strut plates were in-vitro biomechanical studies. The geometry of Rectangular strut conceptually allows for an increased number of screws, stability in three dimensions, and resistance against torque forces while maintaining a low profile and malleability. The 2.0mm titanium 3-D curved angle strut plate allows for almost no movement at the superior and inferior borders with manual torsional and bending forces, as opposed to when a single linear plate is applied to the superior border area. When only one linear plate is placed on the superior border, torsional and bending forces usually cause movement along the axis of plate with buccal-lingual splaying and gap formation at the inferior border respectively. Because the screws are placed in box configuration of 2.0mm titanium 3-D curved angle strut plate on both sides of fracture rather than on a single line, broad platforms are created that may increase the resistance to torsional forces along the axis of the plate.

Because the design of 2.0mm titanium 3-D curved angle strut plate is essentially that of 2.0mm plates connected by reinforcing vertical struts, they may therefore provide greater resistance against gap opening at the inferior border with biting forces compared with when a single plate is applied at the external oblique ridge or superiolateral border. The use of 3D plates in mandibular fractures has not yet become established. Only few follow-up studies are presented in literature with few studies emphasizing easy application, simplified adaptation to bone without distortion or displacement of fracture<sup>6</sup>, simultaneous adaptation at both superior and inferior borders hence less operating time.<sup>21</sup>

### Aims and Objectives of the Study

The patients were evaluated and compared for

1. Stability of fractured segments clinically and radiographically.
2. Post operative occlusion.
3. Post operative complication like infection, wound dehiscence, neurosensory deficits (paresthesia of the area involved), non-union, mal-union, delayed union.

### MATERIALS AND METHODS

**Source of Data:** Twenty patients with mandibular angle fracture reporting to Department of Oral and Maxillofacial Surgery, Govt. Dental college and Srinagar.

#### Materials

##### Group 1

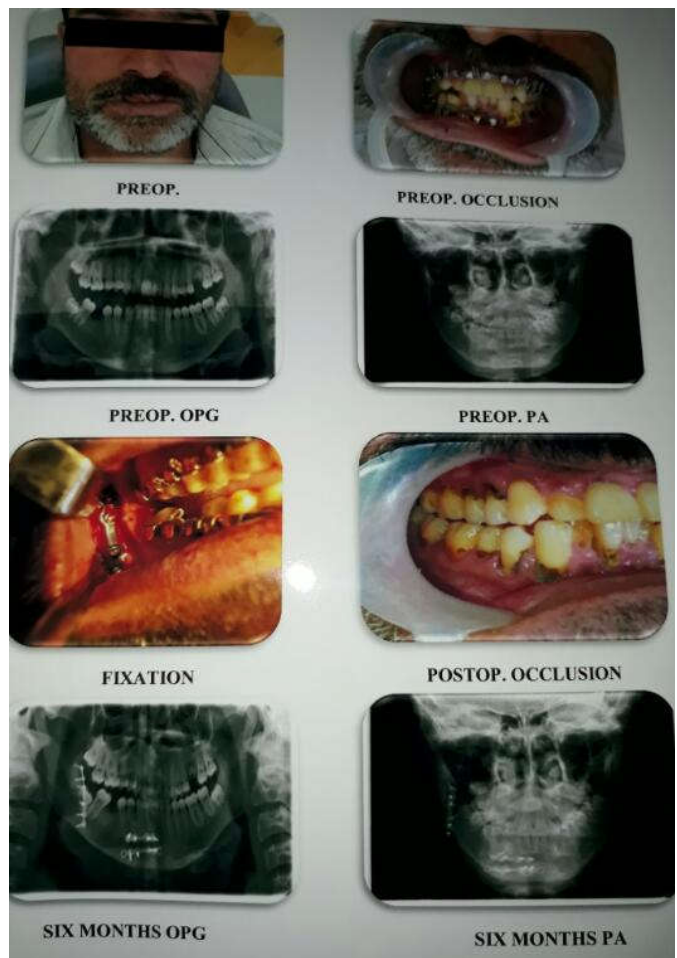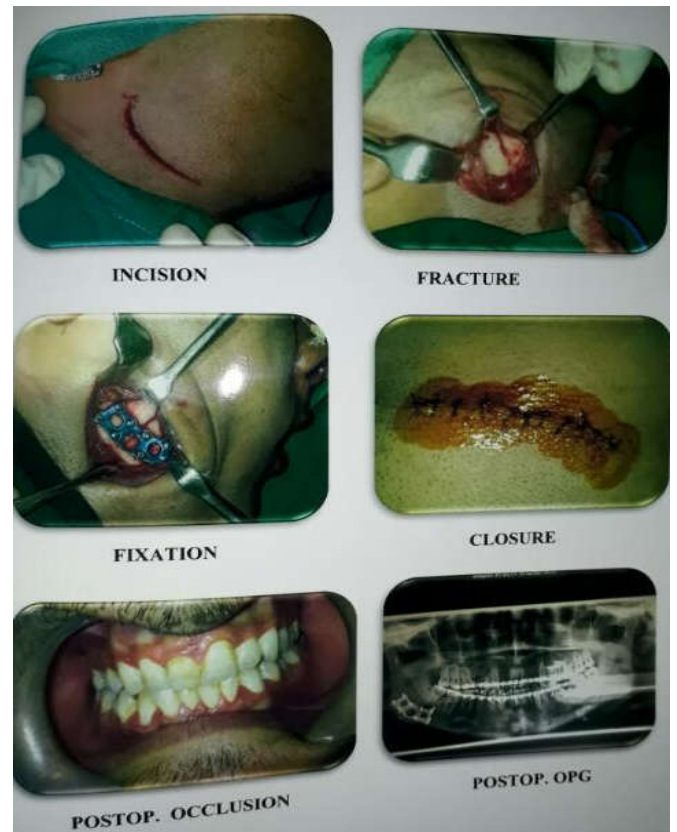2mm titanium 3-dimensional curved angle strut plate.

##### Group 2

2mm titanium 4 hole miniplates.

#### Method

Twenty patients aged more than 18 years will be randomly selected and subjects will undergo Open Reduction and Internal Fixation. Fixation will be done using 2 mm titanium Rectangular curved angle strut plate and 2x6mm titanium screws in ten patients in group A and single miniplate on superior border in ten patients in group B patients



**Inclusion and Exclusion Criteria**

**Inclusion criteria**

1. Adult patients.
2. Single or multiple fractures of mandible requiring open reduction with internal fixation for treatment with angle fracture.
3. Subject willingness.

**Exclusion criteria**

Following patients were excluded  
 Patients with systemic disease contraindicating general anaesthesia.

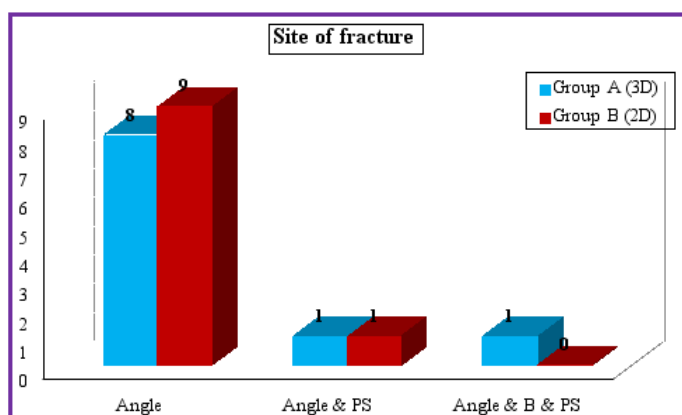
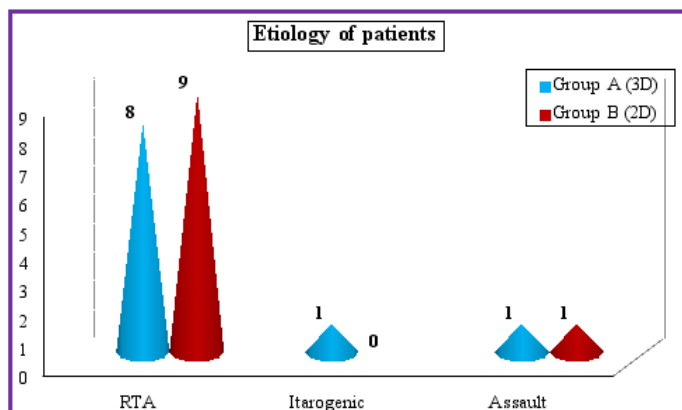
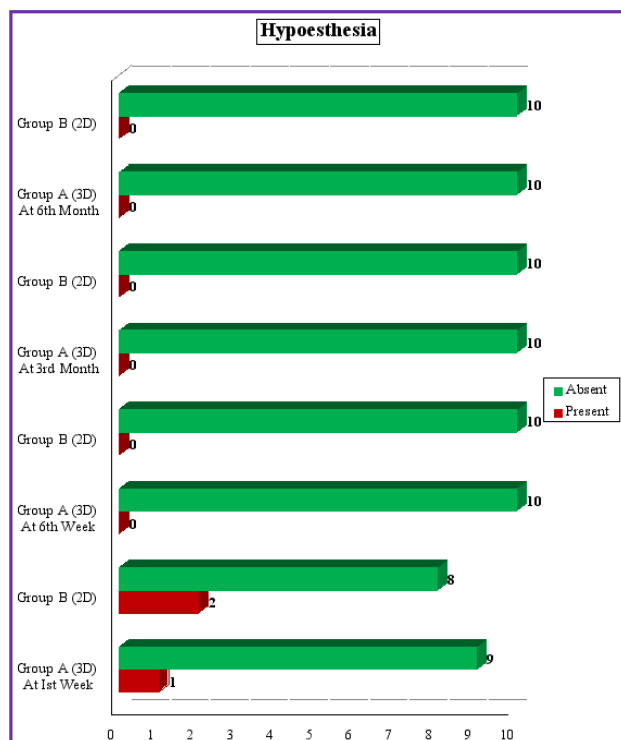
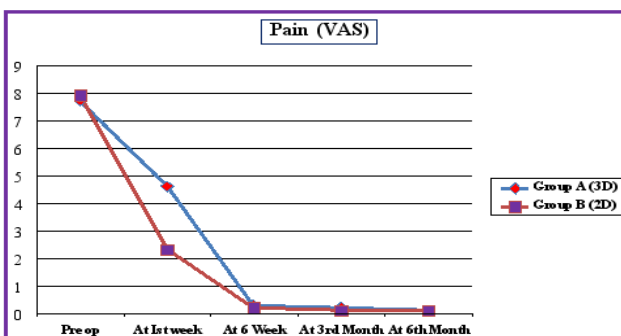
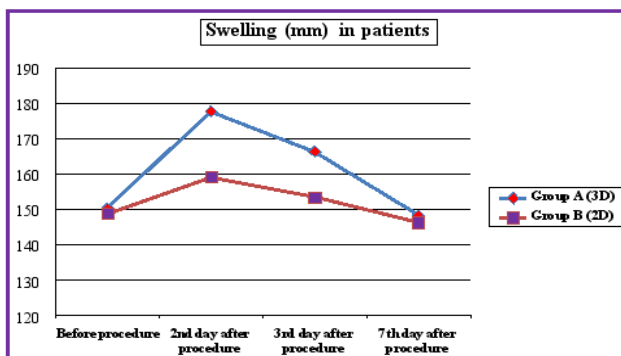
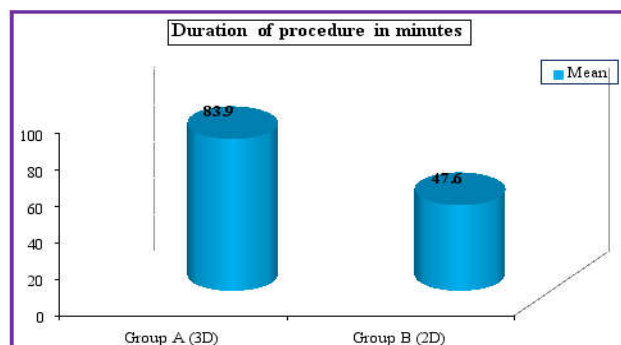
Patients with history of uncontrolled diabetes mellitus, prolonged steroid therapy, Compromised immunity and associated bone pathology Patients with fracture comminution.

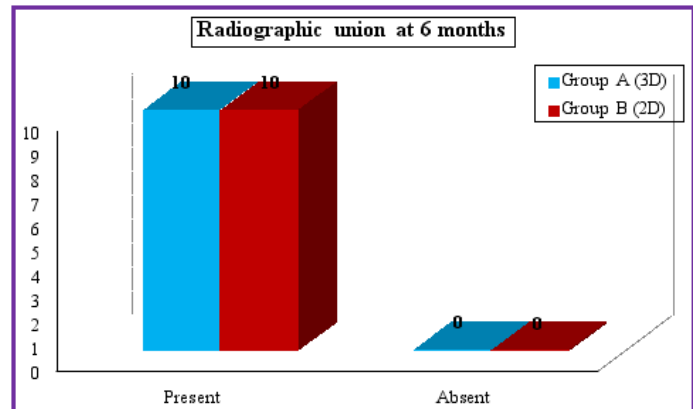
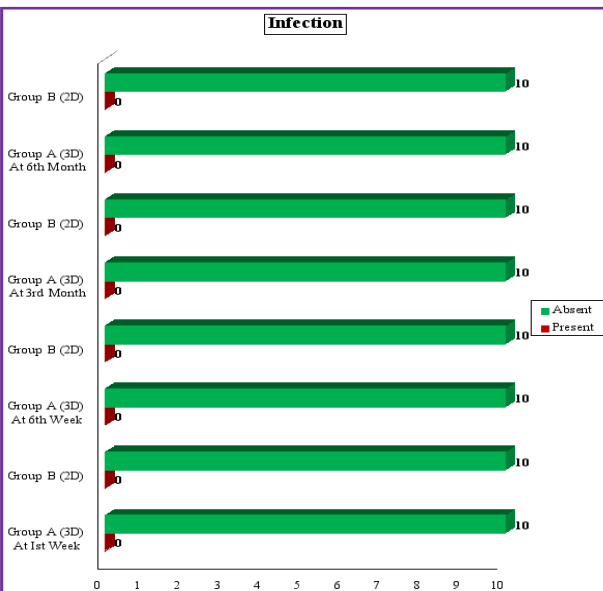
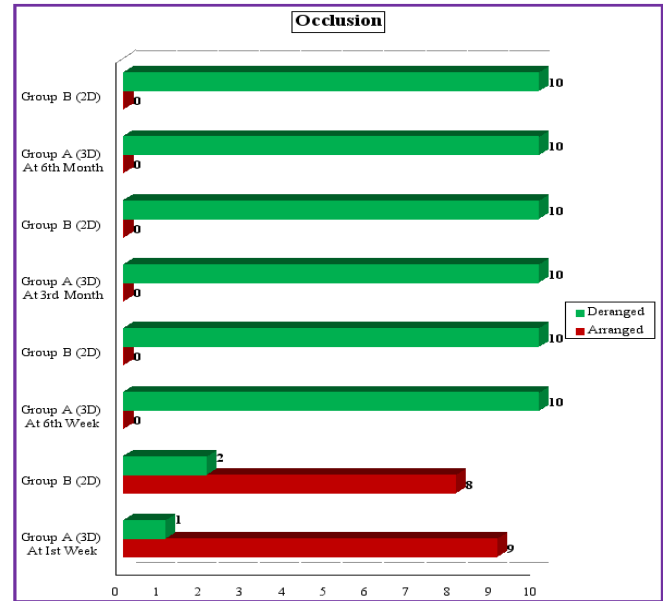
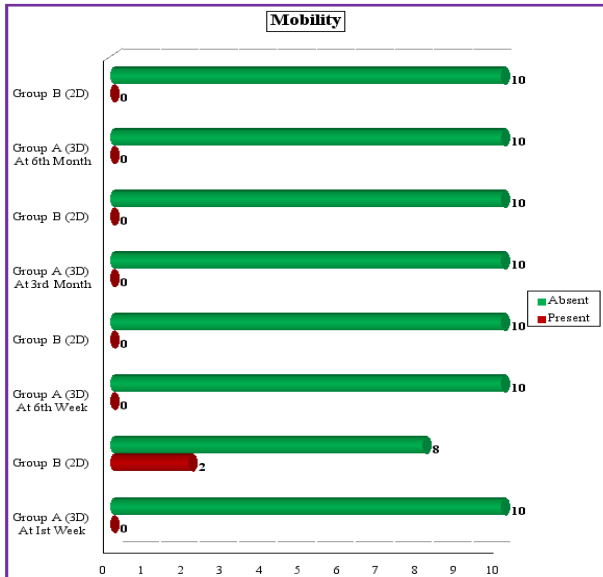
**Evaluation**

Preoperative and post-operative evaluations was done by clinical and radiographic means. It includes:  
 Orthopantomogram (OPG).  
 PA view.

All patients will be followed for a minimum of six months postoperatively.

Clinical assessment will be done on 7<sup>th</sup> day, three weeks, 12 weeks, three months and six months postoperatively.





In our study, in 3D plating group of patients most common cause was RTA, 8 out of 10 (80%) and 2D plating group the most common cause was same 9 out of 10(90%).

In both the groups of patients the most common fracture site was angle, 80% in each group. The mean duration of 3D plating in our study was  $83.9 \pm SD 27.299$  minutes while as in 2D plating  $47.6 \pm SD 6.552$  minutes with p value less than 0.001 which is statistically highly significant. It proves that 2D plating can be accomplished quicker than 3D plating.

Swelling increased after 2<sup>nd</sup> day of procedure and then after decreased up to 7<sup>th</sup> day of the procedure in each group. With statistically insignificant difference in both the groups.

Visual analogue score increased after 2<sup>nd</sup> day of procedure and then after decreased up to 7<sup>th</sup> day of the procedure in each group with statistically insignificant difference in both the groups.

Occlusion at first week, 6 weeks, 3<sup>rd</sup> month and at 6 months were compared in 3D plating and 2D plating groups and it is found statistically insignificant with p value of 1. Paresthesia at first week, 6 weeks, 3<sup>rd</sup> month and at 6 months were compared in 3D plating and 2D plating groups and it is found statistically insignificant with p value of 1. Post-operative infection at first week, 6 weeks, 3<sup>rd</sup> month and at 6 months were compared in 3D plating and 2D plating groups and it is found statistically insignificant with p value of 1. In both the groups none of the

patient developed wound dehiscence. Radiographic evaluations for reductions and fixation were confirmed at first week which was satisfactory in all patients in both the groups. Radiographic evaluation for osteogenic changes was confirmed at 9<sup>th</sup> week after the procedure in both the groups and it was found that there is statistically insignificant difference.

Radiographic evaluation for union or non-union was confirmed at 20<sup>th</sup> week after the procedure in both the groups and it was found that there is statistically insignificant difference.

In both the groups all patients return to their normal activity like speech, Mastication, social interaction in 10 – 14 days with no statistically difference. There is no major difference in terms of treatment outcome in both systems, and both are equally effective in mandibular angle fracture treatment. However, in the symphysis/Para symphysis region, 3D mini plate fixation is an easy-to-use alternative to conventional mini plates in terms of less surgical time and simultaneous stabilization at both the superior and inferior border by one plate; in the angle region, a single conventional mini plate fixed according to Champy's technique is easy to place intra orally with less surgical time and less surgical trauma and has similar clinical results. Because of superior design of 3-D maximum number of screws lie near the fracture site thus providing better stability and thus open up doors for its satisfactory use in the management of displaced fractures.

Although this study is promising but small sample size is limitation of this study. A more comprehensive conclusion can only be drawn when a larger sample size is taken.

## DISCUSSION

Restoration of function and appearance with particular care to re-establish the occlusion is the basic aim of treatment of mandibular fractures. For a long period of time intermaxillary fixation was the only method of treatment. With the introduction of modern anaesthesia, antibiotics and blood transfusion, open reduction with fixation of fragments has become routine in the treatment of fractures with gross displacement, comminution and in the edentulous mandible. Through decades various plate and screw osteosynthesis have been introduced like AO plating system, miniplating system, resorbable plates and screws and 3-D titanium plates.

3D titanium plates have been used sporadically by few surgeons for fixation of the mandibular angle fractures.<sup>6,12</sup> Its use in the maxilla has remained skeptical, with Farmand<sup>6</sup> being the only surgeon to have used them for the maxillary fracture osteosynthesis.

The principle of 3D plate osteosynthesis is:

1. Tissue dissection only in vicinity of planned osteotomy or fracture line
2. The 3D plates are positioned parallel to the osteotomy or fracture line
3. The connecting arms of the plate should be positioned rectangular to the osteotomy or fracture line (Ananad Sanker, Thangaclu 2004)

The use of 3D plates in mandibular fractures has not yet become established. Only few follow-up studies are presented in literature with few studies emphasizing easy application,

simplified adaptation to to bone without distortion or displacement of fracture<sup>6</sup>, simultaneous adaptation at both superior and inferior borders hence less operating time.<sup>21</sup>

Guimond<sup>19</sup> & Jeurgen<sup>20</sup> found the fixation with 3D plates predictable, the plate strong yet malleable facilitating stabilization both at superior and inferior borders. They concluded that 3D titanium plates are an easy to use alternative to conventional mini plates but contraindicated its use in fractures with less inter fragmentary bone contact.

Monocortical miniplate osteosynthesis has been used successfully for the management of facial fractures. Michelet *et al.*<sup>13</sup> developed the concept of miniplate osteosynthesis in the late 1960s. In 1973, they published a report documenting the successful use of a small plate and monocortical screws for the treatment of mandibular fractures. The original goal of miniplate osteosynthesis was to provide stable mandibular fracture reduction without requiring interfragmentary compression or maxillomandibular fixation. Studies performed in the early 1970s at the Groupe d'Etudes en Biomecanique Osseuse et Articulaire de Strasbourg demonstrated that the miniplate achieves this goal by neutralizing undesirable tensile forces while retaining favorable compressive forces during function. Champy *et al.* (1976)<sup>15</sup> elaborated on Michelet's work with the intraoral application of the monocortical miniplate for the treatment of mandibular angle fractures.

The rationale of using monocortical plate in mandibular fracture is that osteosynthesis by plate screwed on the outer cortical plate is solid enough to support the strain developed by masticatory muscle. On the horizontal ramus the masticatory forces create elongation strain along the alveolar border and compressive strain along the lower border within the mandible. Only the traction strain are injurious and have to be neutralized. The study of moments with regards to the mathematical model of mandible (Champy *et al.*, 1978)<sup>14</sup> showed that at the level of horizontal ramus, there are almost only flexion moments, the value of which increases from the front backwards. In the anterior part of mandible, anterior to first premolar, there are mainly moments of torsion. They are higher, the nearer they are to the mandibular symphysis. Therefore, the principle of osteosynthesis is to re-establish, the mechanical qualities of the mandible, taking into account the anatomical conditions.

The clinical effectiveness of 3D plate needs to be verified or substantiated by biomechanical studies. Wittenberg<sup>9</sup> in his biomechanical experiment found that entire 3D titanium plate was formed by joining two miniplates with interconnecting vertical cross bars which reinforced each other, thereby the plate acting as a single unit and interconnections of the plate reduced the vertical displacement and shearing of bone to minimal.

Champy *et al.* (1978)<sup>14</sup>, Cawood (1985)<sup>16</sup>, Smith (1991)<sup>17</sup>, and Kuriakose *et al.* (1996)<sup>35</sup> used miniplate for patients with mandibular fracture and found uneventful healing. The same finding was reported in our study Intermaxillary fixation was done pre-operatively only when needed to achieve the optimum habitual occlusion and post-operative intermaxillary fixation for 1-2 weeks which is in accordance with the many authors.<sup>20,22,23</sup>



## References

1. Michelet FX, Deymes J, Dessus B. Osteosynthesis with miniaturized screwed plates in maxillo-facial surgery. *J Maxillofacial Surgery* 1973; 1:79
2. Raveh J, Vuillemin T, Ladrach K, et al. Plate osteosynthesis of 367 mandibular fractures. The unrestricted indication for the intraoral approach. *J Craniomaxillofacial Surgery* 1987; 15:244
3. Fridrich KI, Pena-Velasco G, Olson RA. Changing trends with mandibular fractures. *J Oral Maxillofacial Surgery* 1992; 50:586
4. Kroon FHM, Mathisson M, Cordey JR, et al. The use of miniplates in mandibular fractures. An in vitro study. *J Craniomaxillofacial Surgery* 1991; 19:199
5. Ellis E, Karas N. Treatment of mandibular fractures using two mini dynamic compression plates. *J Oral Maxillofacial Surgery* 1992; 50:958
6. Farmand M, Dupoirieux L. The value of 3-dimensional plates in maxillofacial surgery. *Rev Stomatol Chir Maxillofacial* 1992; 93:353
7. Ellis E, Walker L. Treatment of mandibular angle fractures using two noncompression miniplates. *J Oral Maxillofacial Surgery* 1994; 52:1032
8. Choi BH, Kyoung NK, Ho SK. Clinical and in vitro evaluation of mandibular angle fracture fixation with the two-miniplates system. *Oral Surgery Oral Medicine Oral Pathology* 1995; 79:692
9. Klotch DW, Gal RL. Repair of mandibular fractures using the 2.0mm system. A review. *J Craniomaxillofacial Trauma* 1995; 1:38
10. Ellis E, Walker L. Treatment of mandibular angle fractures using one non-compression miniplate. *J Oral Maxillofacial Surgery* 1996; 54:863
11. Haug RH, Barber E, Reifeis R. A comparison of mandibular angle fracture plating techniques. *Oral Surgery Oral Medicine Oral Pathology* 1996; 82:257
12. Potter J, Ellis E. Treatment of mandibular angle fractures with a malleable noncompression plate. *J Oral Maxillofacial Surgery* 1999; 57:288
13. Bernard Spiessl. Internal fixation of the mandible. A manual of AO/ASIF principles, 1989; 151.
14. Bagby LW, Janes JM. The effect of compression on the rate of fracture healing using a special plate. *Am J Surg* 1958; 95: 761,
15. Brons R, Boering GJ. Fracture of mandibular body treated by stable internal fixation. *J Oral Surg* 1970; 28: 407.
16. Champy M, Lodde JP, Schmidt R. Mandibular osteosynthesis by miniature screwed plates via a buccal approach. *J Maxillofac Surg* 1978; 6: 14.
17. Mehta et al. Osteosynthesis of mandibular fractures with N-butyl cyanoacrylate: A pilot study. *J Oral Maxillofac Surg*, 1987; 45:393-396 17 29
18. Szabo G., Kovacs A., Pulay G. " Champy plates in mandibular surgery ". *Int J Oral Surg*. 1984 ; 13 : 290-293
19. Rosenberg A, Gratz KW, Sailer HF . Should titanium miniplates be removed after bone healing is complete? *Int. J Oral Maxillofac Surg* 1993; 22: 185-188.
20. Guimond C, Johnson J.V, Marchena J.M.. Fixation of mandibular fractures with a 2.0-mm 3-dimensional curved angle strut plate. *J Oral Maxillofac Surg* 2005;63:209-214.
21. Gunter Lauer, Winnie Pradel, Matthias Schneider & Uwe Eckelt.. new 3-Dimensional plate for transoral endoscopic- assisted osteosynthesis of condylar neck fractures. *J Oral maxillofac Surg* 2007; 65:964-971
22. Juergen zix, Olivier Lieger and Tateyuki Iizuka Use of Straight Curved 3- Dimensional Titanium Miniplates for fracture fixation at the mandibular angle *J Oral maxillofac Surg* 2007; 65;1758-1763
23. Kalfarentzos Evangelos, Deligianni Despoina, Mitros Georgios, Tyllianakis Minos Biomechanical evaluation of plating techniques for fixing mandibular angle fractures; the introduction of a new 3D plate approach Oral and Maxillofacial surgery 2009;1(3):9-144

### How to cite this article:

Shajah Hussain Sheikh et al. 2017, A study on Comparison of Fixation of Mandibular Angle Fractures Using Single Miniplate Versus Curved angle Rectangular Strut plate". A Prospective Randomised Clinical Study. *Int J Recent Sci Res*. 8(12), pp. 22118-22123. DOI: <http://dx.doi.org/10.24327/ijrsr.2017.0812.1204>

\*\*\*\*\*