



ISSN: 0976-3031

Available Online at <http://www.recentscientific.com>

CODEN: IJRSFP (USA)

International Journal of Recent Scientific Research
Vol. 8, Issue, 7, pp. 18236-18241, July, 2017

**International Journal of
Recent Scientific
Research**

DOI: 10.24327/IJRSR

Research Article

EXPRESSION OF P53 AND P73 IN TOOTH GERM, DENTIGEROUS CYST AND AMELOBLASTOMAS

Mimansha Patel*, Abhishek Gouraha., Ankita Sannad., Priyanka Mahaseth.,
Rahul Singh Thakur and Ram Chand Bandla

Department of Oral Pathology and Microbiology Triveni College of Dental Sciences, Hospital and
Research Centre, Bilaspur

DOI: <http://dx.doi.org/10.24327/ijrsr.2017.0807.0473>

ARTICLE INFO

Article History:

Received 15th April, 2017
Received in revised form 25th
May, 2017
Accepted 23rd June, 2017
Published online 28th July, 2017

Key Words:

Ameloblastoma, dentigerous cyst, dental
follicle, p53 isoforms, homolog; p73,
biological markers.

ABSTRACT

To clarify the role of p53 homologs in oncogenesis and cytodifferentiation of odontogenic lesions, expression of p53, p73 was analyzed in tooth germs, dentigerous cyst and ameloblastomas.

Materials and methods: Tissue specimens of twenty tooth germs, twenty dentigerous cyst and twenty ameloblastomas were examined by immunohistochemistry for the expression of p53, p73. Immunohistochemistry test was performed using Peroxidase Detection System.

Results: p53 expression was noted significantly higher in Ameloblastoma as compared to Dentigerous cyst and Tooth germ. P53 expression was significantly higher in tooth germ than dentigerous cyst. The expression of p73 was noted significantly higher in tooth germ as compared to Ameloblastoma and dentigerous cyst. p73 expression was significantly higher in ameloblastoma than dentigerous cyst. All three are independent markers i.e. all are expressed irrespective of the other in various groups. The expression of p53, p73 suggests that all these are independent biological markers with differential expression in all the groups. Variations of predominantly expressed isoforms suggest that p53, p73 might differentially function in odontogenic tissues. Thus, it can be hypothesized that p53 may be used as cell proliferation marker in odontogenic lesions, p73 may play an important role in cytodifferentiation and proliferation.

Copyright © Mimansha Patel et al, 2017, this is an open-access article distributed under the terms of the Creative Commons Attribution License, which permits unrestricted use, distribution and reproduction in any medium, provided the original work is properly cited.

INTRODUCTION

Odontogenic cysts are defined as those cysts, which arise from the enamel organ or their remnants. During and after odontogenesis, these cell remnants are common source of cystic change within the jaw bones. Dentigerous cysts (DC) are the most common developmental odontogenic cysts making up to 16.6% of all jaw cysts (Shear, 1992)¹.

Tumors arising from epithelium of the odontogenic apparatus or from its derivatives or remnants exhibit considerable histological variation and are classified into several benign and malignant entities⁽¹⁻³⁾. Ameloblastoma is the most frequently encountered tumor arising from odontogenic epithelium and is characterized by a benign but locally invasive behavior with a high risk of recurrence^(1, 2, 4). Histologically, ameloblastoma shows considerable variation, including follicular, plexiform, acanthomatous, granular cell, basal cell, and desmoplastic types (1). Several recent studies have detected genetic and cytogenetic alterations in these epithelial odontogenic tumors^(5, 6); however,

the detailed mechanisms of oncogenesis, cytodifferentiation, and tumor progression remain unknown. p53 gene is a well-recognized tumor suppressor gene that is frequently altered in tumors^(7, 8). Its gene product is a transcriptional factor that regulates the expression of genes involved in cell cycle arrest or apoptosis in response to genomic damage or cell stress⁽⁹⁾. Two p53 homolog genes, p63 and p73, have been identified at loci 3q27-29 and 1p36, respectively⁽¹⁰⁻¹²⁾. These genes encode multiple proteins that have a significant degree of sequence homology, particularly in the transactivation, DNA-binding, and oligomerization domains⁽¹⁰⁻¹³⁾. Isoforms derived from two different promoters are named TA and Δ N isoforms. TA isoforms (TAp63 and TAp73) containing the transactivation domain are capable of transactivating p53 target genes and inducing growth arrest or cell death, whereas Δ N isoforms (Δ Np63 and Δ Np73) lacking the transactivation domain exert a dominant negative effect on their TA isoforms and wild-type p53 by blocking their transactivation^(12, 13). Recently, one of Δ Np63 isoforms has been shown to possess a second

*Corresponding author: Mimansha Patel

Department of oral Pathology and Microbiology Triveni College of Dental Sciences, Hospital and Research Centre, Bilaspur

transactivation domain in the C-terminus⁽¹⁴⁾. Although these p53 homologs might have a tumor suppressor function, genetic alterations, such as mutation and loss of heterozygosity (LOH), are less frequent than those associated with p53^(11, 13, 15, 16). In recent studies, up-regulated expression and/or activity of p63 and p73 have been demonstrated in some malignancies⁽¹⁷⁻²⁶⁾. Previous studies have confirmed p53 and its related factors, such as p21WAF1/Cip1, Bax, MDM2, and p14ARF, in tooth germs and ameloblastomas, suggesting that the p53 signaling cascade has an important role in oncogenesis or cytodifferentiation of odontogenic epithelium⁽²⁷⁻³⁰⁾. Recently, several syndromes associated with p63 gene mutations have shown to include various tooth abnormalities of both the primary and permanent dentition^(31, 32). In the present study, expression of p53 and p73 in dentigerous cyst, ameloblastomas as well as in tooth germs was examined by immunohistochemistry to clarify the possible role of these p53 homologs in epithelial odontogenic tumors.

MATERIALS AND METHODS

The present study was carried out in Department of Oral and Maxillofacial Pathology and Microbiology, Triveni Institute of Dental Sciences Hospital & Research Centre, Bodri, Bilaspur, India .The study protocol was approved by our institutional ethical committee. The study included histopathologically diagnosed, 20 cases of tooth germ, 20 cases of dentigerous cyst and 20 cases of Ameloblastoma. Immunohistochemistry was performed on tissues fixed in 10% neutral buffered formalin, paraffin embedded tissue. The sections were cut serially to 5 mm for immunohistochemistry to evaluate for p53 and p73 antigens.

Procedure

Immunohistochemical method for detection of p53, p73 antigen:

For immunohistochemistry, Peroxidase Detection System (Streptavidin-Biotin Detection System HRP-DAB; Product Code: RE7110K, Novocastra kit) was employed. Endogenous peroxidase activity was blocked by treating hydrated sections with 3% H2O2 in methanol for 30 min. The slides were heated in a microwave oven for 10 min in 0.01M sodium citrate buffer (pH 6.0) for antigen retrieval and bench cooled for 20 min and again the same cycle was repeated. To prevent non-specific reactions, sections were incubated with 10% serum for 10min. Pre- diluted p53 antibody (clone DO-7; Product code: N1581, Dako, Denmark) were incubated at room temperature in a humidifying chamber for 60 min and then at 4⁰ C overnight. The applied antibodies were mouse anti-p63 monoclonal antibody (Santa Cruz Biotechnology, Santa Cruz, CA, USA; subclass IgG2a; diluted at 1:100) and rabbit anti-p73 polyclonal antibody (Chemicon, Temecula, CA, USA; diluted at 1:500). This was followed by incubation with secondary biotinylated antibody and streptavidin-peroxidase reagent at room temperature in a humidifying chamber for 30 min. Freshly prepared substrate/chromogen solution of 3, 3’ Diaminobenzidine (mixing 5 ml of concentrated DAB in 50 ml of substrate buffer) was used to visualize the antigen-antibody reaction. Finally, the sections were counterstained in Mayer’s hematoxylin. For control studies of the antibodies, the serial sections were treated with phosphate-buffered saline, mouse anti-L26 (CD20) monoclonal antibody (Nichirei; subclass

IgG2a), and normal rabbit IgG instead of the primary antibodies and were confirmed to be unstained.

Assessment of immunohistochemically stained sections

The cells were considered positive for p53 and p73 antigens if there was an intra-nuclear DAB staining (brown color). All the stained nuclei were scored positive regardless of their intensity of staining. Cells that lacked a clear nucleus were excluded. Minimum of 1000 cells were counted in each section. Tissue sections were scanned at 100 magnification for most heavily labeled p53 and p73 positive cells in the epithelial linings. The cell counts were made on captured image at 400 magnification with conventional light microscope in 10 randomly selected fields. The counting was done by two observers and the mean was taken as a final count. The number of positively stained nuclei was expressed as a percentage of the total number counted. The index of positivity, i.e. Labeling index (LI) was obtained for p53 and p73 protein expression for all the groups.

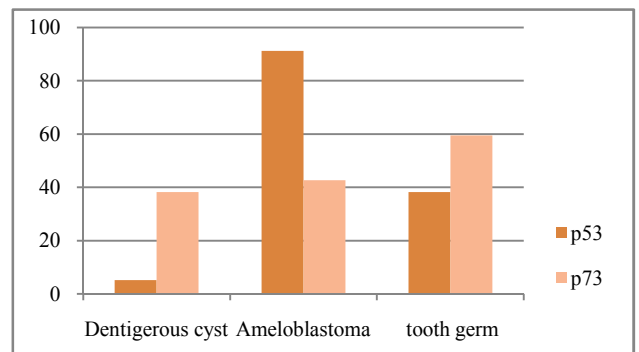
$$p53/p73 (LI) = \frac{\text{Number of IHC Positive Cells (p53, p73)}}{\text{Total number of cells observed}} \times 100$$

Statistical analysis

Group means for Ki-67 LI and p53 LI were derived for each group. The data was analyzed statistically using SPSS 16.0 version software for Windows, Mann-Whitney U-test, Kruskal-Wallis test and Pearson’s rank correlation analysis test. One-way Analysis of Variance (ANOVA), independent student T-test and multiple comparisons using “post-hoc” test were also carried out. The level of statistical significance was at p < 0.05.

RESULTS AND OBSERVATIONS

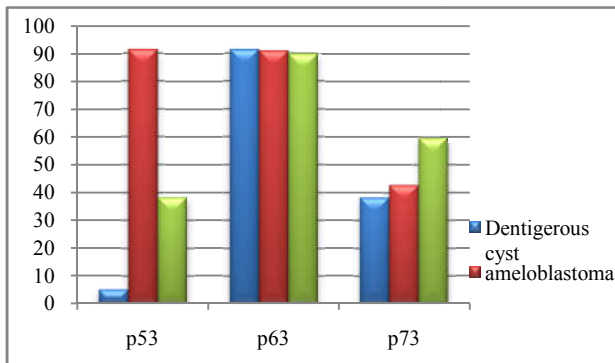
p53 antigen was expressed in 100% of ABs, 100% of DC, 100% of tooth germ. p53 immunolabeling was seen as very few densely stained cells which were sporadically located in the basal cell layer and very few in the suprabasal cell layers in DC and tooth germ. p53 protein was expressed with predominantly dense immunoreactivity in peripheral cells and cells in the central area of the ameloblastic follicle of SMA. (fig)



Graph No. 1 p53 & p73 expression in Dentigerous Cyst, Ameloblastoma & Tooth Germ

Immunohistochemical reactivity for p73 was detected in the nuclei of normal and neoplastic odontogenic epithelial cells; mesenchymal cells in tooth germs and stromal cells in ameloblastomas were faintly reactive with anti-p73 antibody. In tooth germs, expression of p73 was found in most cells of inner and outer enamel epithelium and dental lamina and in fewer cells of stratum intermedium and stellate reticulum (Fig

1a and 2a). Ameloblastomas showed p73 reactivity in most peripheral columnar or cuboidal cells and in fewer central polyhedral cells. Central polyhedral cells in ameloblastomas were far less positive for p73.



Graph No. 2 p53 & p73 expression in Dentigerous Cyst, Ameloblastoma & Tooth Germ

p53 LI were observed in descending order in ABs, tooth germ and DC. p53 LI was significantly higher in ABs than DC ($p < 0.00$) and tooth germ ($p < 0.00$).

p73 LI showed highly significant difference ($p=0.00$).

p73 LI showed a significant difference ($p=0.00$). p73 counts were observed in decreasing order in tooth germ, Ameloblastoma and Dentigerous cysts.

Correlation between p53 LI and p73 LI In dentigerous cyst

p53 and p73 expression showed non significant correlation ($p=0.628$).

In ameloblastoma

p53 and p73 expression showed non significant correlation ($p=0.584$).

In tooth germ

p53 and p73 expression showed non significant correlation ($p=0.503$).

DISCUSSION

In this study, p53 immunolabelling in dentigerous cyst was minimal and seen weakly in the basal cell layers and very few densely stained cells were sporadically located in basal cell layer and only few faintly stained suprabasal cells were seen. p73 immunolabelling was moderate in the basal and parabasal layer with few densely stained cells located in basal cell layer and only few faintly stained suprabasal cells were seen. The immunohistochemical detection of p53 protein indicates an alteration in the p53 protein metabolism probably because of increased production or decreased breakdown of the protein other than mutation. Thus, low p53 positivity suggests that p53 expression is not due to p53 mutation but due to the disturbance of growth regulation leading to stabilization of p53 protein. p73 is a remarkable marker for assessing the neurogenesis as p73 is important for neuronal differentiation and proliferation. Odontogenic epithelium is neuroectodermal derivative. Hence, tooth germ is derivative of neuroectoderm and DC arises when some deviation occurs in the normal odontogenesis process leading to overexpression of p73. This type of staining in Dentigerous cyst could indicate the normal

wild type p53 and p73 protein expression; related to apoptosis and cell proliferation, thus maintaining the regular 2-3 cell layer thickness of epithelium.

This was in accordance with Slootweg *et al* 1995, LI T-J *et al* 1996 who demonstrated that p53 positive cells were detected in all the odontogenic cysts.^{30,32} No study till date have been reported for p73 expression in odontogenic cyst³⁵. The present study results were not consistent with Ogden *et al* 1992 and Lombardi *et al* 1995 who reported that DC were negative for p53 antigen^{29,31}. Variations in findings might be because of the differences in the sampling population, small sample size and sampling technique. Thus, it can be concluded that the mechanism of expansion of Dentigerous cyst could be some distinct factors other than the epithelial proliferation which is often the probable cause of expansion for other cysts. This is confirmed by lack of increased proliferative activity in lining epithelium of DC.

In Ameloblastomas, p53 was highly expressed and p73 was intermediately expressed. p53 immunolabelling was weak to moderate and predominantly in the peripheral cells and only very few weakly stained cells were seen in central area of ameloblastic follicle SMA. Strong and dense p53 immunolabelling was seen in the peripheral cells and most of the central stellate reticulum cells showed weak positive staining and few showed strong positivity. p73 immunoreactivity was seen positive predominantly in the peripheral cells than in the central cells in ameloblastoma. Overexpression of p53 could be because of mutation or enhanced proliferation in short interval of time. As largely elevated expression of p53 is seen in the peripheral cells suggesting alteration of the p53-mdm2-p14^{ARF} cascade leading to proliferation. This could be involved in the oncogenesis, enlargement of lesion and malignant transformation of odontogenic epithelium. p53 mutation probably play a minor role in invasion and cytodifferentiation of Ameloblastoma. It can be hypothesized that the p53 mutation in Ameloblastoma may be sporadic and cumulative.

Enhanced expression of p73 in the peripheral cells of ameloblastoma suggests that p73 plays role in differentiation and / or proliferation of ameloblastoma cells. The present study results were consistent with results of El-sissy *et al* in 1999, Zhong *et al* in 2004, Barboza *et al* in 2005, Vicente *et al* in 2010 who also found weak to moderate p53 LI in periphery and few weakly stained cells in center^{33,36,37}. Kumamoto *et al* in 2005 stated that the immunoreactivity for p63 and p73 in epithelial odontogenic tumours was found evidently enhanced in the peripheral neoplastic odontogenic cells²⁴.

Our hypothesis of p53 mutation playing minor role for development of ameloblastoma was in accordance with the Shibata *et al* in 2002 stated an infrequent p53 gene mutation was seen in limited number of neoplastic cells on ELISA and yeast functional assay³⁹. Kumamoto *et al* in 2004 stated that positive expression of p53 increased with the recurrence and malignant transformation of the ameloblastoma, implying that the p53 mutation might play a minor role in invasion and cytodifferentiation of Ameloblastoma^{24,25}. Our findings were not in accordance with Slootweg who stated that ABs is associated with mutation of p53 gene³⁰. Barnes *et al* in 2004 stated that there was a relatively high frequency (47%) of

allelic loss of tumor suppressor gene (such as p16, pten and p53) found in the development of ameloblastic tumours⁴¹. Judging from these reported results, it remains possible that wild-type p73, but not the mutant forms, may have been expressed in the odontogenic lesions, alluding to the possibility that p73 may play oncogenic role through the expression of wild-type forms rather than as tumor suppressors via the mutant forms.

We put forward following hypothesis for the increase in p73 expression in ameloblastoma. This could be assumed that Δ Np73 might play oncogenic role by inhibiting apoptosis and increasing proliferation in ameloblastoma. Thus it could be hypothesized that Δ Np73 isoform might play a role in oncogenesis of odontogenic epithelium. Our hypothesis was in accordance with the results of Kumamoto *et al* in 2005 who concluded that Δ Np73 mRNA were the major isoform of p73 respectively expressed in all epithelial odontogenic tumours, by the suppression of their transcriptionally active forms i.e. TA isoform^{24,25}.

Mutations of the homologs of p53 i.e. p73 gene are infrequent.⁷ Judging from the previous reported results, it remains possible that wild p73, but not the mutant form, may have been expressed in the odontogenic lesions, it can be hypothesized that there can be a possibility that p73 may play oncogenic role through the expression of wild -type forms rather than as tumor suppressors via the mutant forms.

Over years attempts have been made to investigate the possible correlation between different histologic variants of ameloblastoma and their biologic behaviour. In the present study, plexiform ameloblastoma showed strong immunopositivity for p53 and p73 when compared with follicular ameloblastoma, indicative of increased aggressiveness. This result was in accordance to previous studies conducted by Toryu *et al* in 2004, Kumamoto *et al* in 2005^{36,24}.

In the present study Basal cell Ameloblastoma showed strong positivity for p53 and p73 this was in accordance to the study done by Kumamoto *et al* in 2005 who concluded that, p73 immunoreactivity was slightly higher in basal cell and desmoplastic ameloblastomas than in other subtypes^{24,25}.

However, we believe that comparison of our results may not be useful to assess the kinetic cellular events in cellular kinetic tumours because variations in the methodology. Future studies should be carried out by using a large number of cases of each histological subtype of Ameloblastoma.

In the present study, in tooth germ p53 immunolabelling was least and p73 immunolabelling was intermediate. As tooth germ shows normal odontogenesis so ideally p53 expression should be absent although low expression is still evident due to the continuous proliferation taking place during odontogenesis. This is the wild type of p53. p73 is important in neurogenesis. As odontogenic epithelium is neuroectodermal derivative so there must be a definite role of p63 and p73 in the differentiation of the developing odontogenic epithelium while p53 does not influence the normal odontogenesis.^{37,38} This was in accordance to the Kumamoto *et al* in 2005 who concluded that p53 expression in tooth germs is much lower than the expression of its upstream regulators, mdm2 and p14arf and

p73 are important for epithelial differentiation during tooth development^{24,25}.

Keeping in mind these burning questions study was performed to explore the penetrance of p53 and its paralogue p73 in tooth germ, Dentigerous cyst and ameloblastoma and to clarify the role of p53 and its paralogues in oncogenesis and cytodifferentiation of tooth germ, odontogenic cyst and odontogenic tumours.

p53 expression was highest in Ameloblastoma, intermediate in tooth germ and lowest in Dentigerous cyst. p73 expression was highest in tooth germ, intermediate in Ameloblastoma and least in Dentigerous cyst.

Taking into account of the staining pattern seen in our study and the previous reports it could be hypothesized that, p53 gene mutation might play only minor role and not essential role for neoplastic changes of odontogenic epithelium. The higher expression of p53 in ameloblastoma could be because of the stabilization of the gene thus providing only locally invasive behaviour to the ameloblastomas. There is high proliferative activity noted in the tooth germ indicated by the low expression of p53. This could probably be because of the accumulation of p53 protein³⁹, due to rapidity of cell turn over in a short interval of time, leading to stabilization of p53. In DC, as regular thickness of epithelium is maintained, except for cases of infection, the expression of p53 is minimum, suggesting the stabilization of the p53⁴⁰.

p73 is responsible for the normal neurogenesis incited by the increased expression in tooth germ, a derivative of neuroectoderm. It is also like p63, has a dual role in normal and neoplastic process but the difference comes with the isoform expressed causing variation in staining pattern⁴¹.

CONCLUSION

This study confirmed that p53 signaling cascade, p73 has an important role in the cytodifferentiation and oncogenesis of the odontogenic epithelium and formation of dentigerous cyst and ameloblastoma arises from the aberrations in the normal odontogenesis there is overexpression of the p53 family members in the odontogenic lesions when compared with the tooth germ. Hence, it could be stipulated that p53 family members can be used as prognostic marker in odontogenic lesions.

Future Scope for Research

- Identification of definite isoform of p53 family members involved in a particular lesion.
- Identification of the mutation involved in the p53 family members, if any, in creating other more aggressive odontogenic lesions.
- Number of cases in the study should include more samples of each histological sub-types of Ameloblastoma to assess the correlation, if any, exists between the histological subtypes and the expression of p53 and p73.

References

1. Kramer IRH, Pindborg JJ, Shear M. WHO histological typing of odontogenic tumours. Berlin: Springer-Verlag, 1992; 11-27.

2. Melrose RJ. Benign epithelial odontogenic tumors. *SeminDiagn Pathol* 1999; 16: 271–87.
3. Eversole LR. Malignant epithelial odontogenic tumors. *Semin Diagn Pathol* 1999; 16: 317–24.
4. Sciubba JJ, Fantasia JE, Kahn LB. Tumors and cysts of the jaw. Washington, D.C.: Armed Forces institute of Pathology, 2001; 71-99.
5. Heikinheimo K, Jee KJ, Niini T, *et al.* Gene expression profiling of ameloblastoma and human tooth germ by means of a cDNA microarray. *J Dent Res* 2002; 81: 525-30.
6. Jaakelainen K, Jee KJ, Leivo I, Saloniemi I, Knuutila S, Heikinheimo K. Cell proliferation and chromosomal changes in human ameloblastoma. *Cancer Genet Cytogenet* 2002; 136: 31-7.
7. Finlay CA, Hinds PW, Levine AJ. The p53 protooncogene can act as a suppressor of transformation. *Cell* 1989; 57: 1083-93.
8. Nigro JM, Baker SJ, Preisinger AC, *et al.* Mutations in the p53 gene occur in diverse human tumour types. *Nature* 1989; 342: 705-8.
9. Ko LJ, Prives C. p53: puzzle and paradigm. *Genes Dev* 1996; 10: 1054-72.
10. Kaghad M, Bonnet H, Yang A, *et al.* Monoallelically expressed gene related to p53 at 1p36, a region frequently deleted in neuroblastoma and other human cancers. *Cell* 1997; 90: 809-19.
11. Osada M, Ohba M, Kawahara C, *et al.* Cloning and functional analysis of human p51, which structurally and functionally resembles p53. *Nat Med* 1998; 4: 839-43.
12. Yang A, Kaghad M, Wang Y, *et al.* p63, a p53 homolog at 3q27–29, encodes multiple products with transactivating, death-inducing, and dominant-negative activities. *Mol Cell* 1998; 2: 305-16.
13. Marin MC, Kaelin WG Jr. p63 and p73: old members of a new family. *Biochim Biophys Acta* 2000; 1470: M93-M100.
14. Ghioni P, Bolognese F, Duijf PH, Van Bokhoven H, Mantovani R, Guerrini L. Complex transcriptional effects of p63 isoforms: identification of novel activation and repression domains. *Mol Cell Biol* 2002; 22: 8659-68.
15. Hagiwara K, McMenamin MG, Miura K, Harris CC. Mutational analysis of the p63/p73L/p51/p40/CUSP/KET gene in human cancer cell lines using intronic primers. *Cancer Res* 1999; 59: 4165–9.
16. Ichimiya S, Nimura Y, Kageyama H, *et al.* p73 at chromosome 1p36.3 is lost in advanced stage neuroblastoma but its mutation is infrequent. *Oncogene* 1999; 18: 1061-6.
17. Mai M, Yokomizo A, Qian C, *et al.* Activation of p73 silent allele in lung cancer. *Cancer Res* 1998; 58: 2347-9.
18. Yokomizo A, Mai M, Tindall DJ, *et al.* Overexpression of the wild type p73 gene in human bladder cancer. *Oncogene* 1999; 18: 1629-33.
19. Zaika AI, Kovalev S, Marchenko ND, Moll UM. Overexpression of the wild type p73 gene in breast cancer tissues and cell lines. *Cancer Res* 1999; 59: 3257-63.
20. Parsa R, Yang A, McKeon F, Green H. Association of p63 with proliferative potential in normal and neoplastic human keratinocytes. *J Invest Dermatol* 1999; 113: 1099-105.
21. Crook T, Nicholls JM, Brooks L, O’Nions J, Allday MJ. High level expression of DN-p63: a mechanism for the inactivation of p53 in undifferentiated nasopharyngeal carcinoma (NPC)? *Oncogene* 2000; 19: 3439-44.
22. Hall PA, Campbell SJ, O’neill M, *et al.* Expression of the p53 homologue p63 a and DNp63 a in normal and neoplastic cells. *Carcinogenesis* 2000; 21: 153–60.
23. Hibi K, Trink B, Patturajan M, *et al.* AIS is an oncogene amplified in squamous cell carcinoma. *Proc Natl Acad Sci U S A* 2000; 97: 5462-7.
24. Kumamoto H. Detection of apoptosis-related factors and apoptotic cells in ameloblastomas: analysis by immunohistochemistry and an in situ DNA nick end-labelling method. *J Oral Pathol Med* 1997; 26: 419-25.
25. Kumamoto H, Ooya K. Immunohistochemical analysis of bcl-2 family proteins in benign and malignant ameloblastomas. *J Oral Pathol Med* 1999; 28: 343-9.
26. Kumamoto H, Kimi K, Ooya K. Detection of cell cycle related factors in ameloblastomas. *J Oral Pathol Med* 2001; 30: 309-15.
27. Kumamoto H, Izutsu T, Ohki K, Takahashi N, Ooya K. p53 gene status and expression of p53, MDM2, and p14ARF proteins in ameloblastomas. *J Oral Pathol Med* 2004; 33: 292-9.
28. Celli J, Duijf P, Hamel BC, *et al.* Heterozygous germline mutations in the p53 homolog p63 are the cause of EEC syndrome. *Cell* 1999; 99: 143–53.
29. Brunner HG, Hamel BC, van Bokhoven H. The p63 gene in EEC and other syndromes. *J Med Genet* 2002; 39: 377- 81.
30. Slootweg PJ. P53 protein and Ki-67 reactivity in epithelial odontogenic lesions: an immunohistochemical study. *J Oral Pathology Med* 1995; 24:393-397.
31. Yang A, Schweitzer R, Sun D, *et al.* p63 is essential for regenerative proliferation in limb, craniofacial and epithelial development. *Nature* 1999; 398: 714-8.
32. Li TJ, Browne RM, Prime SS, Paterson IC, Matthews JB. P53 expression in odontogenic keratocyst epithelium. *J Oral Pathol Med* 1996; 25: 245-255.
33. El-Sissy Na *et al.* Immunohistochemical detection of p53 protein in ameloblastoma types. *East Mediterr Health J.* 1999; 5(3):478-89.
34. Nylander K, Vojtesek B, Nenutil R, *et al.* Differential expression of p63 isoforms in normal tissues and neoplastic cells. *J Pathol* 2002; 198: 417-27.
35. Shin DJ, Myoung H, Hwang KK, Kim MJ. Immunohistochemical of p21 and p53 expression in ameloblastoma. *J Korean Assoc Oral Maxillofac Surg.* 2003; 29(4):199-205.
36. Toryu Hirayama *et al.* Immunohistochemical Analysis of Cell Proliferation and Suppression of Ameloblastoma with Special Reference to Plexiform and Follicular Ameloblastoma. *Acta Histochemica Et Cytochemica* 2004; 37(6): 391-398.
37. Kumamoto H, *et al.* p53 gene status and expression of p53, MDM2, and p14 proteins in ameloblastomas. *J Oral Pathol Med.* 2004; 33 (5):292-9.

38. Moghadam B. K.H. *et al*, Immunohistochemical Determination of Tumor - Associated Antigens in Ameloblastoma and Odontogenic cysts. *Acta Medica Irania* 1997; 35(1, 2): 1-7.
39. Shibata T, Nakata D, Chiba I, *et al*. Detection of TP53 mutation in ameloblastoma by the use of a yeast functional assay. *J Oral Pathol Med* 2002; 31: 534-538.
40. Hong Zhang Huang *et al*, Studies on the Invasiveness of Ameloblastoma. *The Chinese Journal of Dental Research* 2009; 12(2): 83-86.
41. Barnes L, Eveson JW, Reichart P & Sidransky D (2005) World Health Organization Classification of Tumours. Pathology and Genetics of Head and Neck Tumours. IARC Press: Lyon.

How to cite this article:

Mimansha Patel *et al.* 2017, Expression of p53 and p73 in Tooth Germ, Dentigerous Cyst and Ameloblastomas. *Int J Recent Sci Res.* 8(7), pp. 18236-18241. DOI: <http://dx.doi.org/10.24327/ijrsr.2017.0807.0473>
