



ISSN: 0976-3031

Available Online at <http://www.recentscientific.com>

International Journal of Recent Scientific Research
Vol. 8, Issue, 3, pp. 15994-15998, March, 2017

**International Journal of
Recent Scientific
Research**

DOI: 10.24327/IJRSR

Research Article

MRI PATTERNS OF HYPOXIC ISCHEMIC ENCEPHALOPATHY IN TERM INFANTS AND CORRELATION WITH NEUROSONOGRAPHIC APPEARANCE & CLINICAL OUTCOME

Priyanka*, Jeevika M.U., Joish Upendra Kumar., Pallavi Sinha., Ramya Konareddy.,
Dipti Kumari and Shivanand H.G

Department of Radio-diagnosis, JJM Medical College, Davangere, India

DOI: <http://dx.doi.org/10.24327/ijrsr.2017.0803.00251>

ARTICLE INFO

Article History:

Received 05th December, 2016
Received in revised form 08th
January, 2017
Accepted 10th January, 2017
Published online 28st March, 2017

Key Words:

Birth asphyxia, Perinatal asphyxia,
Brain injury.

ABSTRACT

MRI is the imaging modality of choice for the diagnosis and follow-up of infants with moderate to severe hypoxic-ischemic encephalopathy. This study was undertaken to evaluate the various MRI patterns of term hypoxic ischemic encephalopathy and to correlate the MRI appearances with clinical outcome. It was also undertaken to compare wherever possible, the neurosonographic appearances with the MRI findings. Differences in the patterns of hypoxic ischemic encephalopathy are likely to result from severity of birth asphyxia. MRI is non-invasive and has no radiation hazards associated with it. The excellent gray – white matter resolution and multiplanar imaging capabilities provide an advantage to MRI over other modalities. The addition of DWI improves the diagnostic capacities of MRI. There is a strong relation between the MRI appearances of birth asphyxia and the clinical outcome. Therefore MRI has a strong role in prognosticating lesions.

Copyright © Priyanka et al, 2017, this is an open-access article distributed under the terms of the Creative Commons Attribution License, which permits unrestricted use, distribution and reproduction in any medium, provided the original work is properly cited.

INTRODUCTION

Perinatal asphyxia, more appropriately known as hypoxic ischemic encephalopathy (HIE) is characterized by clinical and laboratory evidence of acute or subacute brain injury due to asphyxia. The primary causes of this condition are systemic hypoxia and / or reduced cerebral blood flow (CBF). Birth asphyxia causes an estimated 840,000 deaths or 23% of all neonatal deaths worldwide annually.(1,2,3) Despite major advances in monitoring technology and knowledge of fetal and neonatal pathologies, perinatal asphyxia or more appropriately hypoxic ischemic encephalopathy remains a significant condition that cause mortality and long term morbidity.

MRI is the imaging modality of choice for the diagnosis and follow-up of infants with moderate to severe hypoxic-ischemic encephalopathy.(4,5,6,7) Conventional MRI sequences (T1W and T2W) provide information on the status of myelination and pre-existing developmental defects of the brain. When performed after the first day (and particularly after day 4), conventional images may accurately demonstrate the injury pattern as areas of hyperintensity. Conventional images are most helpful at 7-10 days age, when the diffusion – weighted imaging

(DWI) findings have pseudonormalized .DWI allows earlier identification of injury patterns in the first 24-48 hours. MRI is also a useful tool in the determination of prognosis. Studies indicate that infants with predominant injuries to the basal ganglia or thalamus have an unfavourable neurological outcome when compared with infants with a white matter predominant pattern of injury. Both conventional images (T1 and T2 weighted) and diffusion techniques (DWI and ADC maps) have a good specificity (>90%) and positive predictive value (>85%) in predicting death or major disability at age 2 years.

MATERIALS AND METHODS

This is a prospective study. A total of 45 hemodynamically stable term neonates with a clinical staging of HIE, referred to the department of Radio-diagnosis for imaging studies, from pediatric department at tertiary care hospital. The study requires that the patients be adequately sedated to tolerate the prolonged examination time inside the MRI machine.

All patients who fulfill the criteria for the study, referred to the department of Radio diagnosis with clinically suspected Hypoxic Ischemic Encephalopathy in a period of 1 year from July 2015 to June 2016 will be subjected for

*Corresponding author: **Priyanka**

Department of Radio-diagnosis, JJM Medical College, Davangere, India

the study. Study sample was calculated by power based sample size calculation formula.

Following MRI patients were clinically followed up for a period of five months to assess for neurological outcome. The study exclude preterm neonates with birth asphyxia, haemodynamically unstable patients who may not tolerate prolonged examination times in the isolated setting of MRI,

Mri Protocol

The MR imaging protocol is part of our routine protocol and comprise T2W (axial and coronal), T1W (axial), FLAIR (axial), DWI (axial), GRE (axial), SWI (axial) and MRA (TOF-circle of willis and neck). The total imaging time with 1.5T whole body MR imager was approximately 20 minutes 53 seconds and head coil was used.

RESULTS

A total of 45 children underwent for MRI brain. Most of the neonates included in our study belonged to the age group of 6 to 10 days. This study recognizes the limitations imposed because of this selection bias as diffusion findings have been classically known to pseudonormalize after a period of 7 days. 75 % of the patients included in our study were male. The rest were female. 90% of the patients included in our study were normal weight. Only 10 % patients were classed as low birth weight.

Out of 45 babies who were part of the study, 35 babies (77.8%) were clinically staged as Stage II, 6 patients were graded Stage I (13.3%) and 4 out of 45 were categorized as Stage III, corresponding to 8.9% of the total study population. The number of subjects with Grade III injuries that who could be included in the study was less due to the unstable clinical picture associated with the same and the difficulties in obtaining MRI in patients on respiratory support.

Clinical outcome

Out of the 45 patients included in the study, 21 (46.67%) had abnormal outcomes at 5 months follow up, 18 (40%) had normal outcomes at 5 months and 6 (13.33%) were lost to follow up. This study recognizes the limitations of a five month follow up as many of the neurological sequelae of birth asphyxia are known to manifest in a delayed fashion.

MRI findings

Out of 45 patients, 36 patients demonstrated findings positive for HIE. The remaining 9 MRI scans were either normal or demonstrated pathology different from HIE.

Out of these 9 patients, 4 showed presence of subdural haemorrhage, 3 showed evidence of venous sinus thrombosis, 2 patients showed intra - axial hemorrhages.

MRI findings that correlated with HIE in our patients fit into the four categories, i.e. central, periventricular, watershed territory infarcts and mixed findings.

The largest group (17 patients – 37.78%) demonstrated changes in the central structures only. These structures

included the thalami, basal ganglia, internal capsules and the corpus callosum.

The next significant group by numbers was the patient population with mixed findings. 14 patients out of 45 (31.1%) patients had findings that categorized them in the mixed category.

The next group in our study was three study belonged to the watershed infarction corresponding to 6.67% of the study population and two with periventricular changes alone. Two patient in our study belonged to this category, corresponding to 4.44% of the study population.

In a review article titled Prognostic tests in term neonates with Hypoxic Ischemic ncephalopathy: A systematic Review(8), the following results were published. In imaging, diffusion weighted MRI performed best on specificity (0.89 [0.62-0.98]) and T 1 /T2- weighted MRI performed best on sensitivity (0.98 [0.80-1.00]). Magnetic resonance spectroscopy demonstrated a sensitivity of 0.75 (0.26-0.96) with poor specificity (0.58 [0.23-0.87]). The results obtained in our study are in close correlation with the statistical results for MRI published in the review article.

It was also found that neurosonography had a poorer sensitivity compared to MRI as it detected abnormalities in only 44% cases where it was performed as compared to MRI which was abnormal in a much larger percentage of patients. However, the positive predictable value and the specificity are comparable to that of MRI.

Table - 1 Distribution of Neurosonographic Findings

Neurosonogram	Number	Percent
Abnormal	11	24.44
Normal	14	31.11
Not performed	20	44.45
Total	45	100

Table - 2 Mri Pattern of Hie

MRI pattern	Number	Percentage
Central	17	37.78
Mixed	14	31.11
Watershed infarction	3	6.67
Periventricular	2	4.44
Other	9	20

Table - 3 Distribution of Clinical Outcome

Outcome	Number	Percent
Abnormal	21	46.67
Normal	18	40
Lost of Followup	6	13.33
Total	45	100

Table - 4 Correlation of Restricted Diffusion In Posterior Limb of Internal Capsule With Clinical Outcome

Diffusion PLIC	Abnormal outcome	Normal outcome	Lost to follow up	Total
Positive	11	7	2	20

Table - 5 Comparison of Thalamic Diffusion Restriction with Outcome

Diffusion Abnormal Outcome	Normal Outcome	Lost to follow-up
Thalamus Frequency Percentage	Frequency Percentage	Frequency Percentage
Positive 3 100.0	0 0.0	0 0.0

Table - 6 Comparison of Restricted Diffusion in the Basal Anglia with Outcome

Diffusion Abnormal Outcome	Normal Outcome	Lost to follow-up
BG Frequency Percentage	Frequency Percentage	Frequency Percentage
Yes 5 71.43	2 28.57	0 0.0

DISCUSSION

James Barkovich *et al* (9) undertook a study to detect changes of neonatal Hypoxic Ischemic Encephalopathy. They evaluated the results for MRI patterns and divided into four groups based on the tissue structures affected.

- 1) Primarily deep grey matter involvement.
- 2) Primarily cortical injury.
- 3) Periventricular pattern of injury.
- 4) Mixed pattern of injury.

In our study a larger number of patients (20 patients) had restricted diffusion in the posterior limb of the internal capsule as compared to the number of patients (11 patients) who had loss of the normal signal intensity on T1 in the posterior limb of the internal capsule. 55 % of patients with loss of the normal signal in the posterior limb of the internal capsule had abnormal outcomes at 5 months compared to 55.55 % of PLIC diffusion restriction cases. This is in partial concordance with the observations provided by Rutherford *et al* (10) in their studies who found that all patients with abnormal signal intensity in the Posterior limb of the Internal capsule had abnormal neuro developmental outcome.

In our study three out of the 45 patients were found to have restricted diffusion in the region of the thalamus and out of these 3 patients, 1 patient also had T1 hyperintensity in the thalamus. All these patients had abnormal neuro developmental outcomes at 5 months follow up.

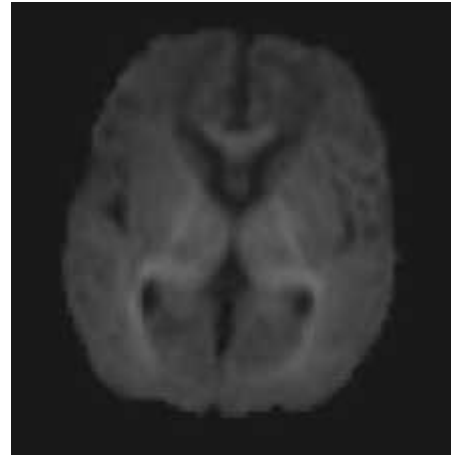
Seven patients had restricted diffusion within the basal ganglia, of which five (71.4%) had abnormal outcomes and 2 patient (28.5%) had a normal outcome.

10 patients had T1 hyperintensity in the basal ganglia of which 7 (70%) had an abnormal outcome, 2 had a normal outcome (20%) and 1 patient (10%) was lost to follow up. Rutherford *et al* (11) conducted studies on infants with history of birth asphyxia. They found that outcome was severe in patients with bilateral basal ganglia abnormalities and our study matches with the data obtained in this study.

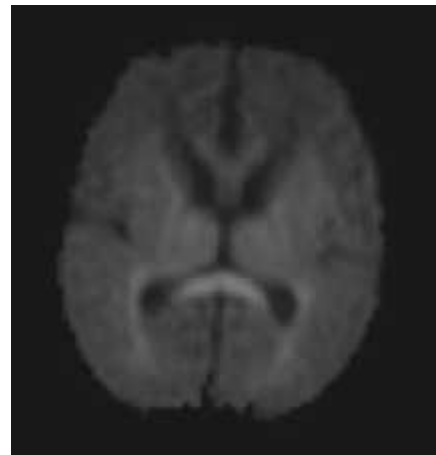Out of 45 neonates, 25 (55.56%) neonates showed presence of restricted diffusion within the splenium of the corpus callosum, 10 neonates (22.22%) showed restriction in the genu and 8 neonates (17.78%) showed restriction in the body. All these three groups had comparable outcomes with outcomes from diffusion restriction in the genu and that in the splenium matching more closely.

It was found that neurosonographic findings correlated poorly with clinical outcome as patients in both groups (those with abnormal and normal neurosonograms) had similar outcomes.

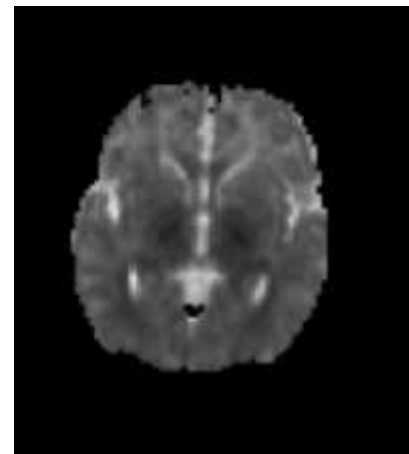
Case 1 Mri Findings In Case of Central Hypoxicischemic Encephalopathy



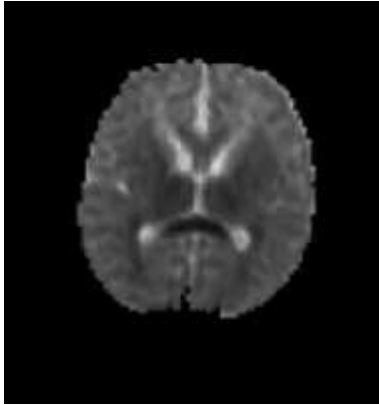
Restricted diffusion in the genu of the corpus callosum and both internal capsules



Diffusion restriction in the corpus callosal splenium

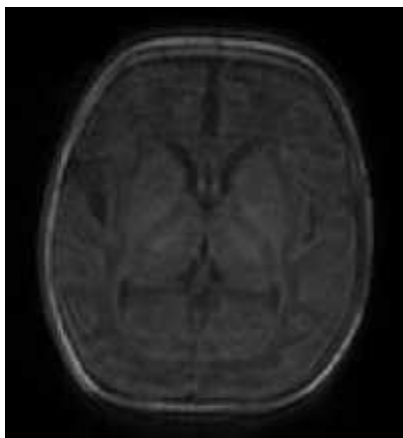


ADC image showing reduced ADC values in the genu of the corpus callosum & both internal capsules



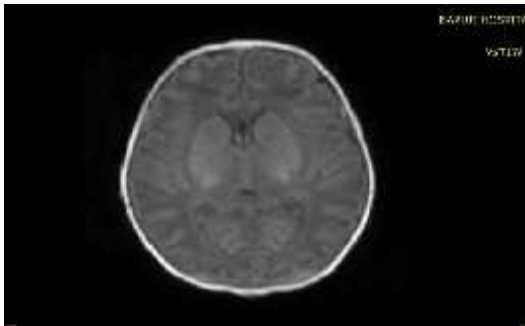
ADC image showing reduced ADC values in the corpus callosal splenium

Diffusion restriction in the corpus callosal splenium

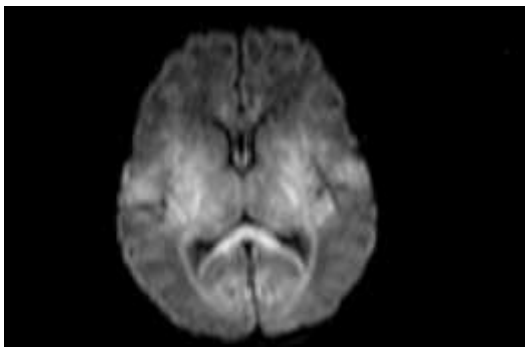


Loss of normal signal intensity in the posterior limb of internal capsule bilaterally on T1W images

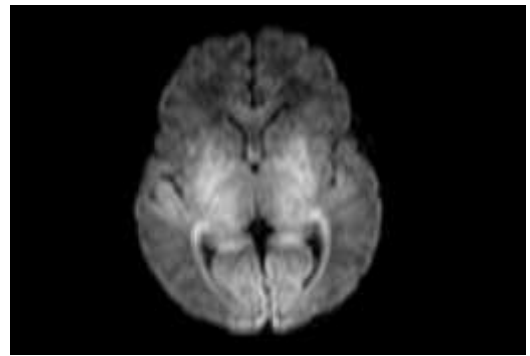
Case 2 Mixed Pattern of Hypoxic Ischemic Encephalopathy in a Neonate



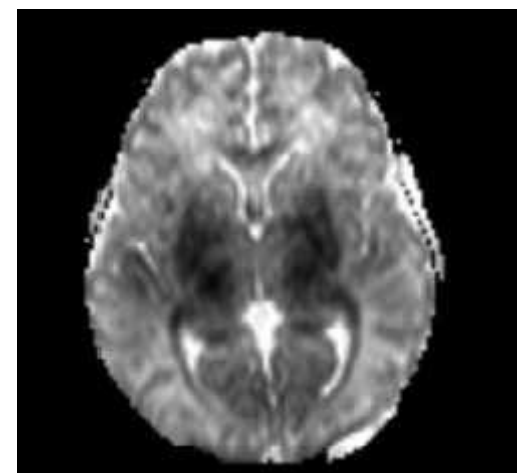
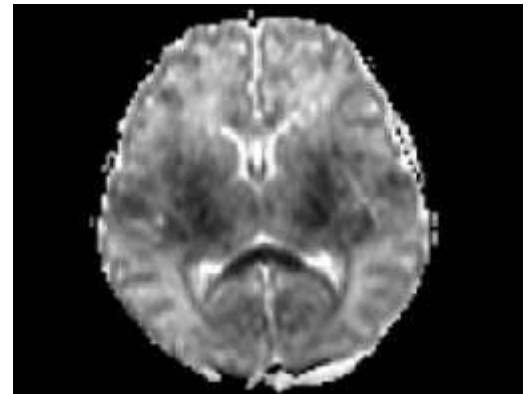
T1 hyperintensity noted involving bilateral basal ganglia



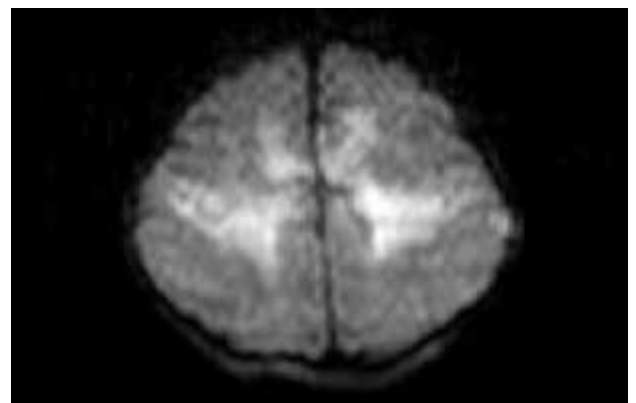
Restriction of diffusion in the splenium of the Corpus Callosum and the posterior limbs of bilateral internal capsules



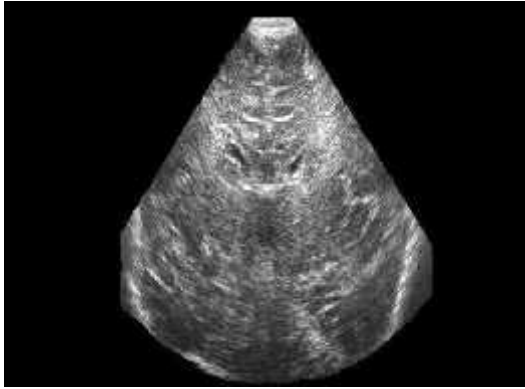
Restriction of water diffusion in thalami and bilateral basal ganglia



Corresponding ADC images showing reduced ADC values



Restricted diffusion in bilateral perirolandic cortices, indicative of cortical involvement



Transfontanelle neurosonogram in the patient reveals increased echogenicity in the region of the basal ganglia and the deep white matter with compression of the ventricles.

Limitation

The limitation of this study is the lack of systematic follow up neuro-imaging. Also patients could be followed up for a maximum of 5 months time at follow up clinics and it has been recognized that subtle neuro-developmental abnormalities can occur years after birth asphyxia.

CONCLUSION

This study attempted to evaluate the various magnetic resonance imaging changes in hypoxic ischemic encephalopathy in term infants. It set out to categorize and suitably classify the various MRI patterns of disease in these patients. Additionally, an attempt to correlate the MRI findings with neurosonographic appearances was undertaken wherever feasible.

It was found that MRI is superior to other imaging modalities in the evaluation of neonatal hypoxic ischemic encephalopathy. There is a strong and consistent correlation between the various MRI findings and the final clinical outcome.

MRI has a high sensitivity and specificity in the evaluation of the above condition. It is non-invasive and has no radiation hazards. It offers excellent gray - white matter resolution which Computed Tomography is incapable of especially in the neonate with a large proportion of unmyelinated brain parenchyma.

Over study found that diffusion weighted imaging adds sensitivity and provides information not seen on the other conventional sequences. Many of the signs of hypoxic ischemic encephalopathy are based on diffusion weighted imaging.

References

1. Ferriero DM. Neonatal brain injury. *N Engl J Med* Nov.42004; 351(19):1985-95.
2. Perlman JM. Brain injury in the term infant. *Semin Perinatol* Dec.2004; 28(6):415-24.
3. Grow J, Barks JD. Pathogenesis of hypoxic - ischemic cerebral injury in the term infant: Current concepts. *Clinical Perinatology Dec.* 2002; 29(4):585-602.
4. Huang BY, Castillo M. Hypoxic - ischemic brain injury: imaging findings from birth to adulthood. *Radiographics* Mar - Apr 2008; 28(2):417-39; Quiz 617.
5. Latchaw RE, Truwit Cue. Imaging of perinatal hypoxic - ischemic brain injury. *Semin Pediatr Neurol Mar* 1995; 2(1):72-89.
6. Rutherford M, Pennock J, Schwieso J, Cowan F, Dubowitz L. Hypoxic ischaemic encephalopathy: early and late magnetic resonance imaging findings in relation to outcome. *Arch Dis Child Fetal Neonatal* Ed.1996; 75:F145-F15.
7. Rutherford M, Biarge MM, Allsop J, Counsell S, Cowan F. MRI of perinatal brain injury. *Pediatr Radiol* 2010; 40(6):819-33.
8. Prognostic tests in Term Neonates with Hypoxic Ischemic Encephalopathy; A systematic Review, Henriette Van Laerhoven, Timo R. De Haan, Martin Offringa, Bart Post and Johanna H. Van der Lee *Pediatrics* 2013; 131:88.
9. A James Barkovich, Kaye Westmark, Colin Patridge, Augusto Sola and Donna M. Ferreiro, *AJNAR Am J Neuroradiol* 16; 427-438, March-95.
10. Rutherford MA, Pennock J, Counsell S *et al.* Abnormal magnetic resonance signal in the internal capsule predicts poor developmental outcome in infants with hypoxic-ischaemic encephalopathy. *Pediatrics*1998; 102:323-328.
11. Rutherford MA, Pennock JM, Murdoch - Eaton DM *et al.* Athetoid cerebral palsy and cysts in the putamen after hypoxic-ischaemic encephalopathy. *Arch Dis Child* 1992; 67:846-850.

How to cite this article:

Priyanka *et al.* 2017, Mri Patterns of Hypoxic Ischemic Encephalopathy In Term Infants And Correlation With Neurosonographic Appearance & Clinical Outcome. *Int J Recent Sci Res.* 8(3), pp. 15994-15998.