



ISSN: 0976-3031

Available Online at <http://www.recentscientific.com>

International Journal of Recent Scientific Research
Vol. 8, Issue, 3, pp. 15876-15884, March, 2017

**International Journal of
Recent Scientific
Research**

Research Article

BIOCHEMICAL AND HEMATOLOGICAL STUDIES ON THE EFFECT OF NEEM (AZADIRACHTA INDICA) LEAVES AQUEOUS EXTRACT ON NEWCASTLE DISEASE VACCINE AND INFECTION IN BROILER CHICKENS

Hager Tarek H. Ismail*

Department of Clinical Pathology, Faculty of Veterinary Medicine, Zagazig University
1 Alzeraa Street, Zagazig City, Sharkia Province, Egypt, Postal Code 44511

DOI: <http://dx.doi.org/10.24327/ijrsr.2017.0803.0002>

ARTICLE INFO

Article History:

Received 15th December, 2016
Received in revised form 25th
January, 2017
Accepted 28th February, 2017
Published online 28th March, 2017

Key Words:

Biochemical, Hematological, Neem,
Newcastle disease, Vaccine

ABSTRACT

The purpose of this study is to investigate the safety of neem leaves aqueous extract and its possible ameliorative and protective effects on broiler chickens vaccinated against NDV and experimentally infected with NDV by assessment of biochemical and hematological parameters, besides histopathological changes. A total of 192 Hubbard chicks were divided equally into eight groups (Gp.1 control group, Gp. 2 vaccinated against NDV, Gp. 3 infected with NDV group, Gp. 4 vaccinated+ infected group, Gp.5 neem aqueous extract administered group, Gp.6 vaccinated+ neem aqueous extract administered group, Gp.7 vaccinated+ neem aqueous extract administered group, Gp.8 vaccinated+ infected+ neem extract administered group). After 42 days from starting of experiment, blood and organs samples were collected and biochemical, hematological tests were done beside the histopathological evaluation.

Broiler chickens infected only with NDV showed hyperproteinemia, hyperglobulinemia, increasing of serum liver enzymes activities, increasing of serum uric acid and creatinine levels, no significant changes in erythrogram, leukocytosis, lymphocytosis and monocytosis besides histopathological changes in hepatic and renal tissues. The vaccinated group showed some of those changes. Neem extract administered group markedly hypolipidemic with normal values for most parameters with improving to them in combination with vaccination and /or infection. Combining of neem leaves aqueous extract with NDV vaccine and/or ND infection ameliorated most of the deteriorating effects induced by them which appeared in the form of improvement of liver and kidney functions beside stimulating of the immune system. There is a need to be publicized neem aqueous extract as a safe medicinal plant with a wide medicinal benefits in poultry farms.

Copyright © Hager Tarek H. Ismail, 2017, this is an open-access article distributed under the terms of the Creative Commons Attribution License, which permits unrestricted use, distribution and reproduction in any medium, provided the original work is properly cited.

INTRODUCTION

Poultry provide human with a good source of protein in the form of eggs and meat, besides the fibres in the form of feathers. Poultry production showed a global growth from backyard farming to advancement poultry farming involving commercial egg and meat production. Outbreaks of the diseases in poultry farms especially the viral diseases create a highly economical loss. One of highly infectious and contagious viral disease of domestic poultry and wild birds is the Newcastle disease which cause highly morbidity and mortality rate which end with sharp economic losses to the poultry industry all over the world (Sonaiya and Swan, 2004).

The great challenge facing the poultry industry worldwide is controlling of Newcastle disease (ND) especially in endemic

areas. The main control system of Newcastle disease via vaccination programmes beside high bio-security measurements. Several intense vaccination programmes applied in the veterinary field add extra stress to birds flocks from birth via introducing many different combinations of NDV vaccine strains which consider as a load on flocks health. Failing to maintain birds flocks in healthy condition leads to failure of most successful vaccination programs. Therefore, the trend towards the use of organic compounds in the form of medicinal plants that help in maintain the birds in healthy condition increased nowadays (Khalifeh and Abu-Basha, 2014).

The use of medicinal plants is gradually gaining importance as natural products have a medicinal values against various diseases and haven't tissues and eggs residual effects. One of widely researched plants is *Azadirachta indica*, commonly

*Corresponding author: Hager Tarek H. Ismail

Department of Clinical Pathology, Faculty of Veterinary Medicine, Zagazig University 1 Alzeraa Street, Zagazig City, Sharkia Province, Egypt, Postal Code 44511

known as neem, belongs to the family Meliaceae and contains various active substances as azadiractin, nimbin, nimbindin, quercetin and others which have antioxidant, antibacterial, antifungal, anthelmintic, insecticidal and antiprotozoal properties beside immunostimulatory effects (Jawad *et al.*, 2013). An aqueous extract of neem leaves (10%) has been recorded to possess anti-viral properties against Newcastle disease virus (NDV), fowl pox and infectious bursal disease (IBD) in addition to significant enhancement of the antibodies production against the NDV and IBD (Sadekar *et al.*, 1998).

The current study was carried out to determine the safety of neem leaves aqueous extract and its possible ameliorative and protective effects on broiler chickens vaccinated against NDV and experimentally infected with NDV by assessment of biochemical and hematological features, besides histopathological changes.

MATERIALS AND METHODS

Experimental Birds

A total of 192 Hubbard chicks (one day old) purchased from El-Dakahlia Company. The birds were wing-banded and reared in a floor based system with wood shavings as litter and at a density 10 birds/m² in experimental units in faculty of Veterinary Medicine, Zagazig University. Lighting was provided continuously along the experiment with cyclic temperatures (minimum, 24°C; maximum, 32°C). Birds were fed on commercially prepared diet, (Starter, grower and finisher) which formulated to meet the nutrient requirements and water supplied *ad libitum*. All experimental procedures were carried out in accordance with the Egyptian laws and university guidelines for experimental animals care and approved by the local authorities (Faculty of Veterinary Medicine, Zagazig University, Egypt).

Vaccines

Laprovect AVI ND HB1+IB freeze-dried live vaccine against Newcastle disease and infectious bronchitis. Manufactured by CEVA-Phylaxia, Hungry

Laprovect ITA-New (ND) inactivated oil emulsified vaccine. Manufactured by CEVA-Phylaxia, Hungry

Laprovect AVI ND LaSota freeze dried modified live virus vaccine. Manufactured by CEVA-Phylaxia, Hungry

Preparation of neem leaves aqueous extract

The neem leaves were harvested from middle aged green trees in agricultural orchards of Faculty of Agriculture, Zagazig University. Leaves were dried in oven at 37°C for 24 hours then dried leaves were ground in metallic grinder and 40 g of dried ground leaves were taken in a non-metallic jar and hot boiled distilled water (1 litre) was poured on it then kept at room temperature for 5-8 hours to prepare the 4% neem aqueous extract (Leila, 1977).

Viral inoculum

Birds were infected experimentally with velogenic viscerotropic Newcastle disease virus (vvNDV) was a locally field isolate, which prepared according to (Sheble and Reda, 1976).

Experimental Design

Birds were randomly divided into eight equal groups and each one containing two replicates (12 birds/ replicate) and were treated differently as the following:

Gp. (1) birds were kept as a control

Gp.(2) birds were vaccinated with AVI ND HB1+IB intraocular by placing one drop of vaccine in the eye at the 5th day of age, then with ITA-New (ND) as 0.5 ml S/C at the 7th day of age then boosted with AVI ND LaSota intraocular by placing 1 drop of vaccine in the eye at 15th day of age.

Gp. (3) birds were inoculated with 0.1 ml of NDV by instillation bilaterally in the conjunctival sac (The stock fluid was adjusted to an infectivity titre of 10⁶ EID₅₀) at 30th day of age. (Brown *et al.*, 1999)

Gp. (4) birds were vaccinated NDV then infected experimentally with NDV at the same dose, route and age of birds in gps.(2 and 3).

Gp.(5) birds given only 50 ml from 4% neem leaves aqueous extract / liter of drinking water for 42 days. (Durrani *et al.*, 2008).

Gp.(6) birds were vaccinated NDV and given neem leaves aqueous extract at the same dose, route and age of birds in gps.(2 and 5).

Gp.(7) birds were infected experimentally with NDV and given neem leaves aqueous extract at the same dose, route and age of birds in gps. (3 and 5).

Gp.(8) birds were vaccinated, infected experimentally with NDV and given neem leaves aqueous extract at the same dose, route and age of birds in gps. (2, 3 and 5).

Birds that infected and uninfected were housed in different places to avoid direct contact between the groups, and bio-security measures were registered to avoid accidental contaminant infections.

Sampling

At the end of experimental study (at 42nd day of age) blood samples were collected from the wing vein of all groups and were divided into two portions. The first portion was collected without anticoagulant for serum separation for biochemical analysis. The second portion was collected into clean Wasserman tubes containing dipotassium salts of ethylenediamine tetraacetic acid for hematological analysis. Birds from each group were euthanized by slaughtering for collecting samples from the liver and kidneys for histopathological examination.

Biochemical tests

Serum was used to determine total proteins (TP) and albumin level, aspartate aminotransferase (AST) and alanine aminotransferase (ALT) activities and triglycerides (TG), total cholesterol (TC), uric acid and creatinine levels. All of these parameters were measured using commercial diagnostic kits purchased from Diamond Diagnostic Company and Spinreact by using Photometer 5010 (Robert Riele GmbH and co-kg,

Germany) except globulins level was estimated by subtracting albumin from total proteins.

Hematological studies

Red blood cells count, packed cell volume (PCV) value, hemoglobin (Hb) concentration, total and differential leukocytic counts were determined by using automated blood cell analyzer (Sysmex XT-2000iV, Kobe, Japan) (Harvey, 2012).

Histopathological evaluation

Liver and kidneys of birds were dissected out, and then fixed in 10% neutral buffered formalin, dehydrated in a graded ethanol series, cleared in xylene and finally embedded in paraffin wax. Paraffin sections of 5 µm thickness were stained by hematoxylin and eosin (H&E) and examined microscopically (Bancroft et al., 1996).

Statistical analysis

All data were performed using SPSS software (v.16). Data were analyzed using one-way analysis of variance (ANOVA), Tukey’s HSD multiple comparison tests was used to test the significance differences between the mean values. Variability in the data was expressed as the pooled SEM and the alpha level for determination of significance was 0.05. Means in the same column followed by different letters were significantly different and the highest value was represented by the letter (a).

RESULTS

Clinical Signs

All experimental birds were clinically monitored daily for any clinical signs from zero day till the end of the experiment. Most of birds in different groups appeared clinically healthy and some birds appeared depressed after vaccination but with no mortality. Some clinical signs appeared in group infected with NDV without any vaccination or neem aqueous extract administration especially from (48 to 72 hpi) such as depression, decreased appetite, sneezing, dyspnoea, conjunctivitis, ruffled feathers and watery diarrhoea. The total mortality in this group was 50% which occurred on days 3-10 PI. Dead broiler chickens were necropsied and gross lesions revealed wide spread of visceral organs congestion and enlargement.

Serum biochemical parameters

The data obtained in Table 1 clarified that serum total proteins level of broiler chickens groups (vaccinated against NDV, infected with NDV, administered neem leaves aqueous extract only, vaccinated against NDV plus administration of neem leaves aqueous extract) was highly significant increase in compare with control group. Non significant change was observed in this parameter in broiler chickens

Table 1 Some biochemical parameters of broilers chickens in gps. (1-8) after 42 days of starting experimental study

Groups	Parameters								
	Total proteins (g/dl)	Albumin (g/dl)	Globulins (g/dl)	AST (U/L)	ALT (U/L)	TG (mg/dl)	TC (mg/dl)	Uric acid (mg/dl)	Creatinine (mg/dl)
Gp.(1)	3.32 ^c	1.77 ^{ab}	1.55 ^d	78.63 ^d	10.44 ^{abc}	53.48 ^{bc}	157.57 ^{ab}	6.08 ^e	0.59 ^e
Gp.(2)	4.15 ^a	1.79 ^a	2.36 ^{ab}	116.99 ^b	9.69 ^c	49.22 ^c	156.61 ^{ab}	6.39 ^e	0.59 ^e
Gp.(3)	4.01 ^{ab}	1.79 ^a	2.22 ^{ab}	181.41 ^a	11.17 ^{ab}	48.56 ^c	160.93 ^a	8.09 ^a	1.46 ^a
Gp.(4)	3.75 ^{abc}	1.72 ^{ab}	2.03 ^{bc}	124.45 ^b	9.95 ^c	57.32 ^{abc}	160.24 ^{ab}	6.52 ^{bc}	0.57 ^e
Gp.(5)	4.15 ^a	1.83 ^a	2.32 ^{ab}	88.92 ^{cd}	10.64 ^{abc}	33.05 ^d	137.98 ^d	6.05 ^e	0.47 ^e
Gp.(6)	4.08 ^a	1.63 ^b	2.45 ^a	94.85 ^c	10.05 ^{bc}	55.62 ^{abc}	144.43 ^{cd}	6.42 ^e	0.51 ^e
Gp.(7)	3.94 ^{abc}	1.64 ^b	2.30 ^{ab}	118.92 ^b	11.57 ^a	63.26 ^{ab}	152.06 ^{bc}	7.61 ^{ab}	0.84 ^b
Gp.(8)	3.41 ^{bc}	1.75 ^{ab}	1.66 ^{cd}	121.84 ^b	11.52 ^a	65.01 ^a	155.60 ^{ab}	5.99 ^e	0.53 ^e
SEM ¹	0.06	0.01	0.06	4.80	0.13	1.65	1.34	0.14	0.05
p-value	0.000	0.000	0.000	0.000	0.000	0.000	0.000	0.000	0.000

Means bearing different superscripts within the same column are significantly different (P<0.05).

¹SEM: Standard error of the mean

Gp. (1) Control group, Gp. (2) Vaccinated group, Gp. (3) Infected group, Gp. (4) Vaccinated+infected group, Gp. (5) neem leaves aqueous extract administered group, Gp. (6) Vaccinated+ neem leaves aqueous extract administered group, Gp. (7) Vaccinated+ neem leaves aqueous extract administered group, Gp. (8) Vaccinated+ infected+ neem leaves aqueous extract administered group, AST= Aspartate aminotransferase, ALT= Alanine aminotransferase, TG= Triglycerides, TC= total cholesterol.

Table 2 Some hematological parameters of broilers chickens in gps. (1-8) after 42 days of starting experimental study.

Groups	Parameters							
	RBCs (×10 ³ /µl)	Hb (g%)	PVC (%)	T.L.C (×10 ³ /µl)	Lymphocytes (×10 ³ /µl)	Heterophils (×10 ³ /µl)	Monocytes (×10 ³ /µl)	Eosinophils (×10 ³ /µl)
Gp.(1)	2.37 ^a	7.40	29.40	25.04 ^c	11.41 ^c	12.44 ^{bc}	0.66 ^{bc}	0.53
Gp.(2)	2.51 ^a	7.58	30.26	28.83 ^{ab}	16.05 ^a	10.63 ^c	1.22 ^a	0.93
Gp.(3)	2.49 ^a	7.52	30.09	28.12 ^b	14.30 ^b	12.15 ^{bc}	1.28 ^a	0.39
Gp.(4)	2.51 ^a	7.64	30.52	27.76 ^b	13.75 ^b	12.59 ^b	0.94 ^{ab}	0.48
Gp.(5)	2.53 ^a	7.96	30.76	26.79 ^{bc}	13.35 ^b	12.23 ^{bc}	0.66 ^{bc}	0.55
Gp.(6)	2.68 ^a	8.51	33.30	30.97 ^a	14.49 ^{ab}	14.67 ^a	0.98 ^{ab}	0.83
Gp.(7)	2.36 ^a	7.73	30.38	28.19 ^b	14.12 ^b	12.88 ^{ab}	0.51 ^c	0.68
Gp.(8)	2.70 ^a	8.56	32.99	27.92 ^b	13.85 ^b	12.69 ^b	0.73 ^{bc}	0.65
SEM ¹	0.03	0.10	0.39	0.35	0.27	0.24	0.05	0.05
p-value	0.042	0.815	0.123	0.000	0.000	0.000	0.000	0.143

Means bearing different superscripts within the same column are significantly different (P<0.05).

¹SEM: Standard error of the mean

Gp. (1) Control group, Gp. (2) Vaccinated group, Gp. (3) Infected group, Gp. (4) Vaccinated+infected group, Gp. (5) Neem aqueous extract administered group, Gp. (6) Vaccinated+ neem leaves aqueous extract administered group, Gp. (7) Vaccinated+ neem leaves aqueous extract administered group, Gp. (8) Vaccinated+ infected+ neem aqueous extract administered group, RBCs=Red blood corpuscles, PVC=Packed cell volume, Hb=Hemoglobin, T.L.C.=Total leukocytic count

Groups (vaccinated against NDV plus the infection with NDV, administered neem leaves aqueous extract plus infection with NDV and vaccinated against NDV plus the infection with NDV plus administration of neem leaves aqueous extract). Serum albumin level showed non significant change in all groups in compare with control group.

Serum globulins level showed highly significant increase in all groups in compare with control one except broiler chickens group which exposed to vaccination plus infection with NDV plus administration of neem leaves aqueous extract showed non significant change in compare with control group. Serum AST activity showed highly significant increase in all groups except the broiler chickens group (administered neem leaves aqueous extract only) in compare with control group. Serum ALT activity revealed non significant change in all groups in compare with control group. Serum triglycerides level showed highly significant decrease in broiler chickens group administered neem leaves aqueous extract only and highly significant increase in broiler chickens group vaccinated against NDV plus infection with NDV plus administration of neem leaves aqueous extract in compare with control group. Serum total cholesterol level showed highly significant decrease in broiler chickens groups (administered neem leaves aqueous extract only and vaccinated against NDV plus administration of neem leaves aqueous extract) in compare with control group. Serum uric acid and creatinine levels showed highly significant increase in broiler chickens groups (infected with NDV only and infected plus administration of neem leaves aqueous extract) in compare with control group.

Hematological parameters

Erythrogram was detailed in Table 2, there is no statistical significant change was shown in the number of erythrocytes, hemoglobin concentration and packed cell volume in all groups in compare with control group.

Leukogram was detailed in Table 2, there is highly significant increase in total leukocytic and lymphocytic counts in all groups in compare with control one. The highest value of leukocytic count presented in broiler chickens group (vaccinated against NDV plus administration of neem leaves aqueous extract) followed by broiler chickens group (vaccinated against NDV only), while the highest value of lymphocytic count presented in broiler chickens group (vaccinated against NDV only) followed by broiler chickens group (vaccinated against NDV plus administration of neem leaves aqueous extract). Heterophils count showed highly significant increase in broiler chickens group (vaccinated against NDV plus administration of neem aqueous extract) and non significant change in other experimental groups in compare with control group. Monocytes count showed highly significant increase in broiler chickens groups (vaccinated against NDV only and infected with NDV only) and non significant change in other experimental groups in compare with control group. Eosinophils counts showed no statistical significant change between experimental groups.

DISCUSSION

Poultry production has been developed significantly in the recent years and plays an important role in the countries

economies. Newcastle disease (ND) considers as the most significant viral disease of poultry all over the world. Vaccination is a routine work for ND control in commercial chicken flocks in several countries. The needs for medicinal plants have been increased all over the world as they available and affordable for most of farmers, consider as a good natural antimicrobial, lowering blood cholesterol level in addition to its important role in improving performance, growth and feed conversion rates and weight gain in avian species. Neem (*A. indica*) is one of medicinal plants which are currently under wide extensive research. Neem leaves aqueous water extract was recorded to has anti-viral properties and plays an important role in strengthening the immune system of the body (Ayodele *et al.*, 2013 and Jawad *et al.*, 2013).

Serum proteins are important blood compartment which share in diagnosis and evaluation of the nature and progress of several diseases (Lumeij, 2008) Hyperproteinemia which was observed in almost of broiler chickens groups associated mainly with increasing of serum globulins level. Hyperglobulinemia may be associated with immunoglobulin formation due to immune system response of broiler chickens to vaccination against NDV, infection with NDV and administration of neem leaves aqueous extract (Zoth *et al.* 2008; Eze *et al.*, 2014; Singh *et al.*, 2014), the highest value presented in broiler chickens group received vaccination plus neem leaves aqueous extract which indicates the synergistic immunomodulatory action of both of them.

Although measurement of serum enzymes activities is very important diagnostic tool of different health disturbance in avian species, a lot of enzymes activities difficult to interpret. AST enzyme considers as very sensitive non specific biomarkers of hepatic disease in birds (Perelman, 1999). ALT activity occurs in a number of different tissues. Specific diagnostic value of ALT enzyme is poor in avian species (Najafi *et al.*, 2014). In the present study, serum AST activity was increased in broiler chickens groups vaccinated against NDV vaccine and infected with NDV, this may indicate damage to hepatic tissues and various organs (McDaniel and Chute, 1971) especially visceral organs in infected group (Rivetz *et al.*, 1975). The highest value observed in infected group without any vaccination and treatment. These results were confirmed by histopathological changes of liver in vaccinated group, which showing extensive mononuclear cell infiltration (Arrows) in the portal area with sever congestion (Arrowhead) (Fig. 1) and histopathological changes of liver in infected group, which showing portal congestion (Black arrow), leukocytic infiltration (Black arrowhead), diffuse coagulative necrosis (Red arrow) and focal leukocytic aggregation (Red arrowhead) (Fig. 2). Neem leaves aqueous extract administered group showed non significant change in activity of this enzyme which mean no harmful or toxic effect for this medicinal plants on hepatic tissue and different organs (Jawad *et al.*, 2014). Combining administration of neem leaves aqueous extract plus vaccination against NDV vaccine or infection with NDV reduced serum AST activity in compare with groups which vaccinated or infected only may indicate protective action of different neem leaves aqueous extract constituents which able to correct the physiological disorders caused by ND vaccine or NDV infection. These results were

confirmed by histopathological changes of liver in group administered of neem leaves aqueous extract plus vaccination, which showing mild portal congestion (Arrows) with mild leukocytic infiltration (Arrowheads) (Fig. 4) and histopathological changes of liver in group administered of neem leaves aqueous extract plus infection, which showing apoptotic hepatic cell (Arrow) with proliferation of Von Kupffer cells (Arrowheads) (Fig. 5).

cholesterol levels showed highly significant decrease in neem leaves aqueous extract administered group in compare with control group may be due to inhibition of fatty acid synthesis which leads to reduction in the level of triglycerides (Ahsan *et al.*, 1999), while indirect inhibitory effects of active principles of neem at the level of HMG-CoA reductase, which considers a key enzyme in cholesterol biosynthesis lead to lowering cholesterol level (Ogbuwu *et al.*, 2009).

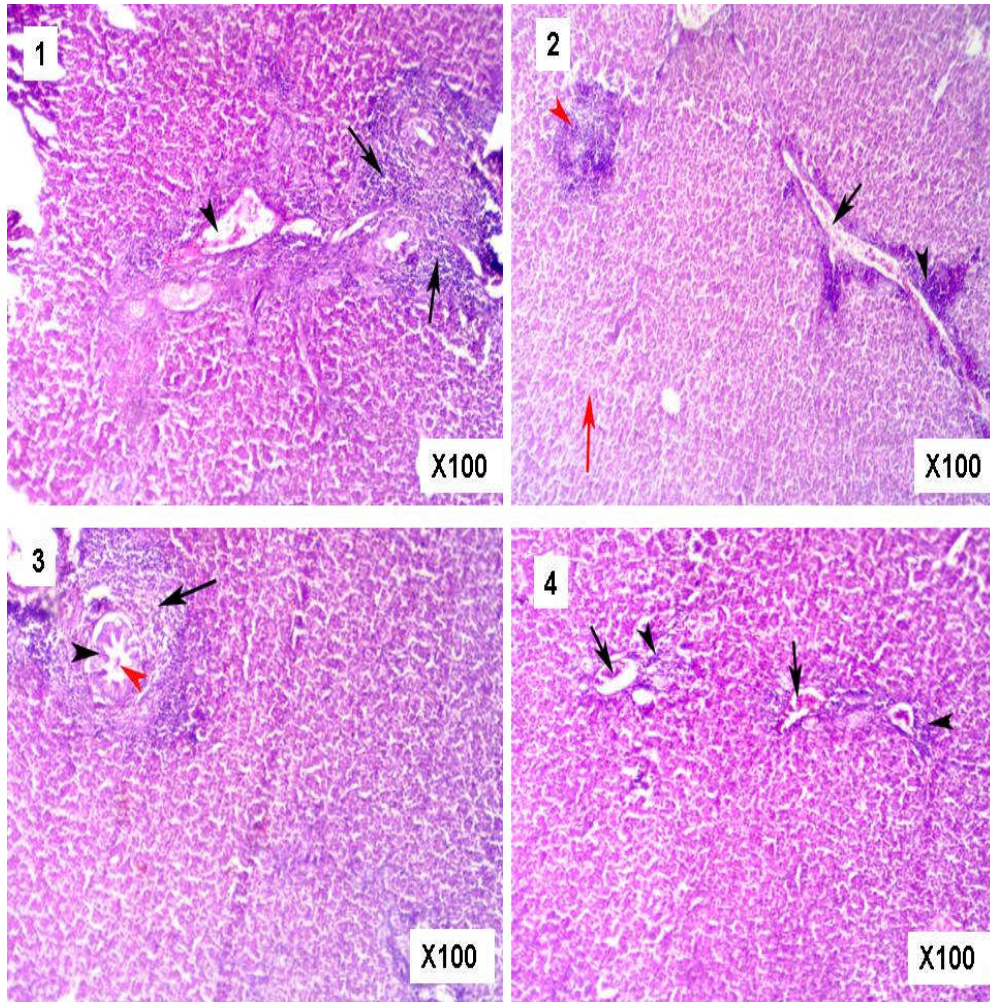


Fig. 1 Liver of broiler chicken in gp. (2) showing extensive mononuclear cell infiltration (Arrows) in the portal area with sever congestion (Arrowhead), H&E stain, X100

Fig. 2 Liver of broiler chicken in gp. (3) showing portal congestion (Black arrow), leukocytic infiltration (Black arrowhead), diffuse coagulative necrosis (Red arrow) and focal leukocytic aggregation (Red arrowhead) H&E stain, X100

Fig. 3 Liver of broiler chicken in gp. (4) showing leukocytic infiltration in the portal area (Arrow), with slight hyperplasia of lining epithelium of bile duct (Arrowhead), with presence of eosinophilic material in lumen of bile duct (Red arrowhead) , H&E stain, X100

Fig. 4 Liver of broiler chicken in gp. (6) showing mild portal congestion (Arrows) with mild leukocytic infiltration (Arrowheads), H&E stain, X100

Also, combining of vaccination with NDV infection showing leukocytic infiltration in the portal area (Arrow), with slight hyperplasia of lining epithelium of bile duct (Arrowhead), with presence of eosinophilic material in lumen of bile duct (Red arrowhead) (Fig. 3) and combining of vaccination plus NDV infection and neem leaves aqueous extract showing focal leukocytic aggregation (Arrow) (Fig. 6) in liver of this groups. Serum ALT activity showed insignificant increase in groups infected with NDV either alone or in combination with neem leaves aqueous extract either alone or with ND vaccine may indicate some sort of injury to the liver and other organs.

Serum lipids concentration is an important marker of lipid metabolism. In this study, serum triglycerides and total

Furthermore, the hypolipidemic action of neem leaves aqueous extract and low-level of lipid in broilers chickens have great benefits on human health as a meat consumer (Ademola *et al.*, 2009). Groups which vaccinated against NDV and infected with NDV either alone or in combining with each other or neem leaves aqueous extract showed non significant changes in those parameters in comparison with the control group and highly significant increase in compare with group administered neem aqueous extract only may reveal that the importance of using neem aqueous extract as hypolipidemic agent.

Serum creatinine and uric acid levels are used mainly as markers of renal functions and indicators to different degrees of damage to kidney histological structure (Dunnill, 1974). Serum

uric acid level is the primary marker of renal functions in avian species (Tully *et al.*, 2009). This study showed a highly significant increase in the values of these parameters in infected broilers with NDV may be due to severe kidney damage (Najafi *et al.*, 2014). Hyperuricemia may be due to injury of the tubular endothelial cells. Over 80 % of nitrogen excreted by birds is in the form of uric acid through tubular secretion (Okorie-Kanu *et al.*, 2016). Renal lesions due to NDV have been determined in several avian species (El-Bahrawy, 2016). These results were confirmed by histopathological changes of kidney, which showing focal coagulative necrosis

with replacement of necrotic tissue with mononuclear cells (Arrow) (Fig. 7) and cortical hemorrhage (Arrows), with shrinkage of glomeruli (Arrowheads) (Fig. 8). Non significant change in these parameters in groups vaccinated against NDV vaccine only, administered neem leaves aqueous extract only, or received both of them indicate no adverse effect of vaccination and neem extract constituents on the renal functions. Broiler chickens group which infected with NDV plus administration of neem leaves aqueous extract showed significant increasing in same parameters, but with lesser degree may be due to renal protective activity of neem leaves extract (Singh *et al.*, 2014) as it is rich in flavonoids

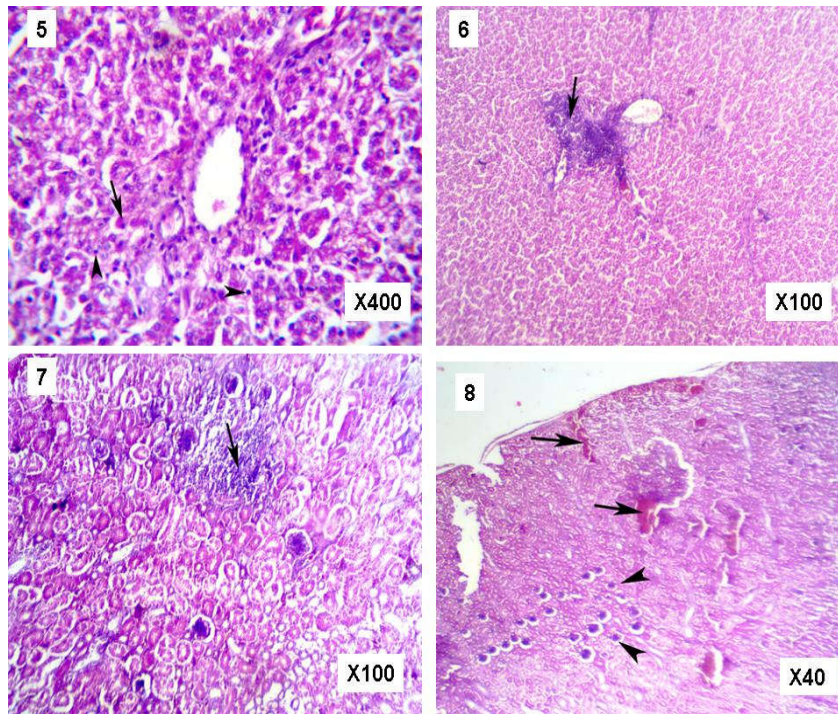


Fig. 5 Liver of broiler chicken in gp. (7) showing apoptotic hepatic cell (Arrow) with proliferation of Von Kupffer cells (Arrowheads), H&E stain, X400
Fig. 6 Liver of broiler chicken in gp. (8) showing focal leukocytic aggregation (Arrow), H&E stain, X100
Fig. 7 Kidney of broiler chicken in gp. (3) showing focal coagulative necrosis with replacement of necrotic tissue with mononuclear cells (Arrow), H&E stain, X100.
Fig. 8 Kidney of broiler chicken in gp. (3) showing cortical haemorrhage (Arrows), with shrinkage of glomeruli (Arrowheads) H&E stain X40

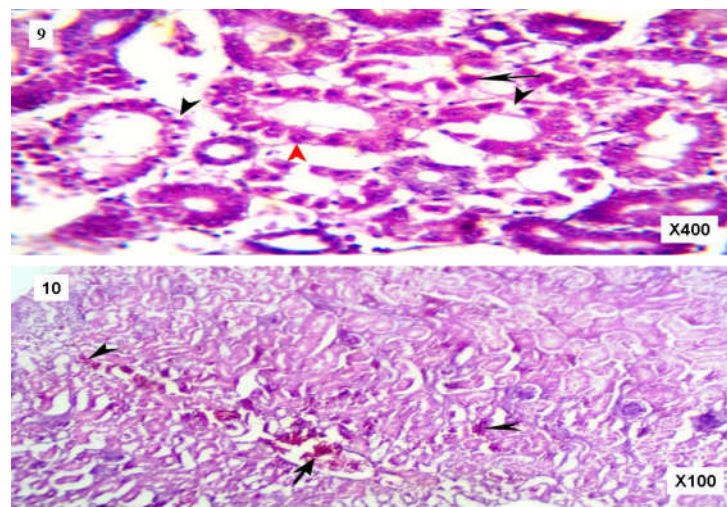


Fig. 9 Kidney of broiler chicken in gp. (4) showing pyknosis (Arrow),hydropic degeneration (Arrowheads) and apoptosis (Red arrowhead) of renal tubules epithelium. H&E stain, X400.
Fig. 10 Kidney of broiler chicken in gp. (7) showing congetion (Arrow) and focal haemorrhage (Arrowheads), H&E stain, X100.

(rutin, quercetin, flavonoglycosides, polyphenols, and tannins) which play a vital role in protection against renal injury via anti-inflammatory and antioxidant activities (scavenging free radicals) (Dkhil *et al.*, 2013; Kitdamrongtham *et al.*, 2014) beside its potential anti-viral activity. These results were confirmed by histopathological changes of kidney, which showing congestion (Arrow) and focal haemorrhage (Arrowheads) (Fig. 10). Insignificant increase in serum uric acid level in broilers group vaccinated against NDV and infected with NDV may indicate reduction severity of viral infection in vaccinated birds which help in reduce its harmful effect on renal tissue. These results were confirmed by histopathological changes of kidney, which showing pyknosis (Arrow), hydrobic degeneration (Arrowheads) and apoptosis (Red arrowhead) of renal tubules epithelium (Fig. 9).

Hemogram has helped in the diagnosis of several avian species diseases coupled with history and clinical signs. According to the results of this study, there is no statistical significant change in erythrogram parameters in all experimental groups which may indicate no harmful effects of vaccination against NDV and neem leaves aqueous extract on these parameters in different birds groups.

At same time, non significant variation in these parameters in broiler chickens after infection with NDV was reported in other studies (Rwuaan *et al.*, 2009; Igwe *et al.*, 2013). The variation in erythrogram parameters during infection depends on the NDV strain and its pathogenic characteristics (Badau *et al.*, 2015). Also, hypovolemia which may have resulted from fluid loss due to diarrhea that observed in this disease may falsely increase these parameters and masked any case of anemia in NDV infected groups.

Leukocytosis which observed in the present study across most of broiler chickens groups related mainly to lymphocytosis. which occurred as a result of immunostimulatory effect of vaccination (Latimer, 2011), marked responding to antigenic stimulation which resulted from viral infection (Doneley, 2011) and enhancement of the immune response via proliferation of lymphocytes by active neem leaves aqueous extract constituents (Kwawukume *et al.*, 2013) in vaccinated, infected, neem aqueous extract administered broiler chickens groups, respectively.

Heterophils count usually indicates the severity of the initial immune response. Increasing heterophils count after administration of birds neem meal recorded previously by (Esonu *et al.*, 2006; Nayaka *et al.*, 2013). Administration of neem aqueous extract combining with vaccination and/or infection induced insignificant increase in heterophils count in compare with groups vaccinated or infected only may be resulted from the possible protection action of neem against heterophils apoptosis as NDV exhibit high-level of apoptosis (Ravindraa *et al.*, 2009). The result of this study agrees with (Obianuju *et al.*, 2015).

Monocytosis in this study revealed that successful immunological reaction of the body against the vaccine virus in vaccinated broiler chickens group (Simpraga *et al.*, 2008) and transition of monocytes from bone marrow to the tissues as macrophages for mopping up of necrotic debris in infected broiler chickens group (Thomson, 1984).

In general, given leukogram revealed that highest degree from leukocytosis in broiler chickens group which vaccinated against NDV plus administration of neem leaves aqueous extract may represent synergistic action of both of them to stimulate of the immune system of birds.

CONCLUSION

From the present research study it is concluded that biochemical and hematological values obtained from broiler chickens which administered neem leaves aqueous extract fell within normal ranges. This is a good indication that the used concentration of neem aqueous extract hasn't any hazard on birds health. In addition to hypolipidemic activity of neem leaves aqueous extract which has great benefits on human health as a meat consumer. Combining of neem leaves aqueous extract with NDV vaccine and/or ND infection ameliorated most of the deteriorating effects induced by them which appeared in the form of improvement of liver and kidney functions besides stimulating of the immune system. There is a need to be publicized neem aqueous extract as a safe medicinal plant with a wide medicinal benefits in commercial poultry farms.

Acknowledgment

The author would like to express their thanks towards Dr. Mohamed M. Metwally assistant professor of pathology, Faculty of Veterinary Medicine at Zagazig University for his valuable help in examining and reading of histopathological slides. The author acknowledges the assistance of the staff members in the department of virology, Faculty of Veterinary Medicine at Zagazig University in provision of the viral isolates and materials for this study.

References

- Ademola, S. G., Farinu, G.O. and Babatunde, G.M. (2009): Serum lipid, growth and haematological parameters of broilers fed garlic, ginger and their mixtures. *World Journal of Agricultural Sciences*, 5 (1): 99-104.
- Ahsan, U. H., Meraj, K. A. and Rasool, S. (1999): Effect of supplementing *Allium sativum* (Garlic) and *Azadirachta indica* (Neem) leaves in broiler feeds on their blood cholesterol, triglycerides and antibody titre. *Int. J. Agri. Biol.*, 3:125-127.
- Ayodele, P. O., Okonko, I. O., Odu, N. N. and Bansa, A. (2013): Antiviral effect of *Anthocleista nobilis* root extract on the biochemical indices of poultry fowls infected with Newcastle disease virus (NDV). *Ann. Biol. Res.*, 3 (1):20-30.
- Badau, S. J., Hassan, S. U., El-Yuguda, A. and Igbokwe, I. O. (2015): Experimental intraocular infection of exotic cockerels with field strain of velogenic Newcastle disease virus in Nigeria. *J. Adv. Vet. Anim. Res.*, 2(4): 418-426.
- Bancroft, J.D., Stevens, A. and Turner, D.R. (1996): Theory and Practice of Histological Technique. 4th ed., Churchill, Livingstone, New York and London.
- Brown, C., King, D. J. and Seal, B. S (1999): Pathogenesis of Newcastle disease in chickens experimentally infected with viruses of different virulence. *Vet. Pathol.*, 36: 125-132.
- Davis, A. K., Cook, K.C. and Altizer, S. (2004): Leukocyte profiles in wild House Finches with and without

- mycoplasmal conjunctivitis, a recently emerged bacterial disease. *Eco. Health*, 1: 362–373.
- Dkhil, M. A. , Al-Quraishy, S. , Abdel Moneim, A. E. and Delic, D. (2013): Protective effect of *Azadirachta indica* extract against *Eimeria papillata*-induced coccidiosis. *Parasitol. Res.*, 112(1):101–106.
- Doneley, B. (2011): Avian Medicine and Surgery in Practice. Companion and Aviary Birds. 2nd ed., Taylor & Francis group. Boca Raton. FL.
- Dunnill, M. S. (1974): A review of the pathology and pathogenesis of acute renal failure due to acute tubular necrosis. *J. Clin. Pathol.*, 27(1): 2-13.
- Durrani, F. R., Chand, N., Jan, M. , Sultan, A. , Durrani Z. and Akhtar, S. (2008): Immunomodulatory and growth promoting effects of neem leaves infusion in broiler chicks. *Sarhad J. Agric.*, 24 (4):655-659.
- El-Bahrawy, A., Zaid, A., Sunden, Y., Sakurai, M., Ito, H., Ito, T. and Morita, T. (2016): Pathogenesis of renal lesions in chickens after experimental infection with 9a5b Newcastle disease virus mutant isolate. *Vet. Pathol.*, 54(1):94-98.
- Esonu, B. O., Okoli, I. C., Opara, M. N., Obikaonu, H. O., Udedible, C. , Iheshiulor, O. O. M. (2006): Physiological response of laying birds to neem leaf meal- based diets: Body weight organ characteristics and hematology. *Online J. Health Allied Sci.*, 5:1-7.
- Eze, C.P., Shoyinka, V.S.O., Okoye, J. O. A. , Ezema, W. S., Ogbonna, I.O., Eze, D. C., Okwor, E.C. and Ikejiofor, O. K. (2014): Comparison of the serum proteins and immune responses of velogenic Newcastle disease virus infected chickens and ducks. *Open J. Vet. Med.*, 4(6):122-128.
- Harvey, J.W. (2012): Veterinary Hematology: A Diagnostic Guide and Color Atlas. Elsevier Saunders, Missouri.
- Igwe, O. A., Ezema, W. S., Ibu, J. I. and Okoye, J. O. A. (2013): Comparative study of the haematology and persistence of velogenic Newcastle disease in chickens and guinea fowls. *Res. Opin. Anim. Vet. Sci.*, 3: 136-142.
- Jawad, Z. , Younus, M., Rehman, M., Maqbool, A., Munir, R. , Muhammad, K. ,Korejo, R. A. and Qazi, I. H. (2013): Effect of neem leaves (*Azadirachta indica*) on immunity of commercial broilers against Newcastle disease and infectious bursal disease. *Afr. J. Agric. Res.*, 8(37): 4596-4603.
- Jawad, Z. , Younus, M., Rehman, M. U., Munir, R., Maqbool, A. , Shahzad , W., Masood, S. and Muhammad, K. (2014): Effect of *Azadirachta indica* on the hepato-renal functions in broilers chickens. *J. Anim. Plant Sci.*, 24(4): 1012-1018.
- Khalifeh, M. S. and Abu-Basha, E. A. (2014): Boosting Newcastle disease vaccination efficacy under field conditions by aromatic plant essential oil extracts. *Vet. Sci. Dev.*, 4(2):51-57.
- Kitdamrongtham, W., Ishii, K., Ebina, K., Zhang, J., Ukiya, M. and Koike, K. *et al.*, (2014): Limonoids and flavonoids from the flowers of *Azadirachta indica* var. *siamensis*, and their melanogenesis-inhibitory and cytotoxic activities. *Chem. Biodivers.*, 11(1):73–84.
- Kwawukume, A. A., Aning, K. G., Awuni, J. A., Otsyina, H. and Awumbila, B. (2013): The effects of *Azadirachta indica* (Neem) leaf extract on white blood cell count and the immune response of chickens vaccinated with Newcastle disease vaccine. *Int. J. Curr. Sci.*, 7: 23-31.
- Latimer, K.S. (2011): Duncan & Prasse's Veterinary Laboratory Medicine: Clinical Pathology. 5th ed., Wiley-Blackwell, USA.
- Leila, S. F. M. (1977): A Manual on Some Philippine Medicinal Plants (Preparation of Drug Materials). U. P. Bot. Soci.
- Lumeij, J. T. (2008): Avian Clinical Biochemistry. In: Kaneko, J.J., Harvey, J.W. and Bruss, M.L., Eds., Clinical Biochemistry of Domestic Animals, 6th ed., Academic Press, San Diego.
- McDaniel, L.S. and Chute, H. L. (1961): Enzyme activity levels in chickens plasma. *Am. J. Vet. Res.*, 22:99-103.
- Najafi, H. , Ghalyanchi-Langeroudi, A. , Hashemzadeh, M. , Madadgar, O. , Karimi, V. , Khaltabadi-Farahani, K. R. and Maghsoudlo, H. (2014): Comparison of laboratory parameters in the serum of SPF chickens infected with different iranian genotypes of infectious bronchitis virus. *Iranian Journal of Virology* 8(2,3): 1-6.
- Nayaka, H. B. S., Umakantha, B., Ruban, S. W., Murthy, H. N. N. and Narayanaswamy, H. D. (2013): Performance and hematological parameters of broilers fed neem, turmeric, vitamin e and their combinations. *Emir. J. Food Agric.*, 25 (6): 483-488.
- Obianuju, O., William, E., Rita, U., James, E., Ukamaka, E., Chinwe, A., Augustine, O. , Riona, O. and Augustine, N. (2015): Immunologic and haematologic effects of methanolic stem bark extract of *Azadirachta indica* on chickens experimentally infected with velogenic Newcastle disease virus (kudu 113) strain. *Anim. Res. Int.*, 12(3): 2274 – 2283.
- Ogbuwu, I. P., Okoli, I. C. and Iloeje, M. U. (2009): Effect of neem (*Azadirachta indica*) leaf meal on serum metabolite profiles of male rabbits. *Revista UDO Agrícola*, 9(4), 986-991.
- Okorie-Kanu, C.O. , Okorie-Kanu, O. J. and Okoye , J. O. A. (2016): Blood biochemistry responses of ducks infected with a velogenic Newcastle disease virus. *Comp. Clin. Pathol.* , 25:681–688.
- Perelman, B. (1999): Health Management and Veterinary Procedures. In: Deeming, D.C. Ed. The Ostrich, Biology, Production Health. CABI Publishing, New York, USA, pp:321-346.
- Ravindra, P.V., Tiwari, A. K., Ratta, B., Bais, M. V., Chaturvedi, U., Palia, S. K., Sharma, B. and Chauhan, R. S. (2009): Time course of Newcastle disease virus – induced apoptotic pathways. *Virus Res.*, 144: 350 – 354.
- Rivetz, B., Bogin, E., Hornstein, K. and Merdinger, M. (1975): Biochemical changes in chicken serum during infection with strains of Newcastle disease virus of differing virulence. I. Enzyme study. *Avian Pathol.*, 4:3, 189-197.
- Rwuuan, J. S., Rekwot, P. I., Abdu, P. A., Eduvie, L. O. and Obidi, J. A. (2009): Effects of a velogenic Newcastle disease virus on packed cell volume, total protein and hemagglutination inhibition antibody titers of vaccinated Shikabrown cocks. *Int. J. Poult. Sci.*, 8(12): 1170-1173.
- Sadekar, R.D., Kolte, A.Y., Barmase, B.S. and Desai, V.F. (1998): Immune potentiating effects of *Azadirachta indica*

- [neem] dry leaves powder in broilers, naturally infected with IBD virus. *Indian J. Exp. Biol.*, 36(11):1151-1153.
- Sheble, A. and Reda, I. M. (1976): Isolation and characterization of a local velogenic viscerotropic strain of Newcastle disease virus. M.V.Sc. Thesis, Fac. of Vet. Med., Cairo University.
- Simpraga, M., Novak, I.L., Mazija, H., Stokovic, I. and Vojta, A. (2008): Hematological and biochemical parameters of ostriches after vaccination against Newcastle disease. *Period. Biol.*, 110: 91-94.
- Singh, M. K. , Singh, S. K. , Sharma, R. K. , Singh, B. , Palod, J., Kumar, S., Barwal, R. S., Pato, R. A., Kaushal, S. and Joshi, S. K. (2014): Effect of supplementation of neem (*Azadirachta indica*) leaf powder on haemato - biochemical parameters in guinea fowls. *Indian Vet. J.*, 91 (10): 41 – 44.
- Sonaiya, E. B. and Swan, S. E. J. (2004): Manual small-scale poultry production, technical guide manual.FAO Animal production and Health (Food and Agriculture Organization of the United Nations), Rome, Italy.
- Thomson, R.G. (1984): General Veterinary Pathology. 2nd ed., W.B. Saunders Comp., Philadelphia
- Tully, T., Dorrestein, G. M. and Jones, A. K. (2009): Handbook of avian medicine. 2nd ed., Elsevier/Saunders.
- Zoth, S. C., Gomez, E., Carrillo, E. and Berinstein, A. (2008): Locally produced mucosal IgG in chickens immunized with conventional vaccines for Newcastle disease virus. *Braz. J. Med. Biol. Res.*, 41(4):318–323.

How to cite this article:

Hager Tarek H. Ismail.2017, Biochemical and Hematological Studies on the Effect of Neem (*Azadirachta Indica*) Leaves Aqueous Extract on Newcastle Disease Vaccine and Infection in Broiler Chickens. *Int J Recent Sci Res.* 8(3), pp. 15876-15884.