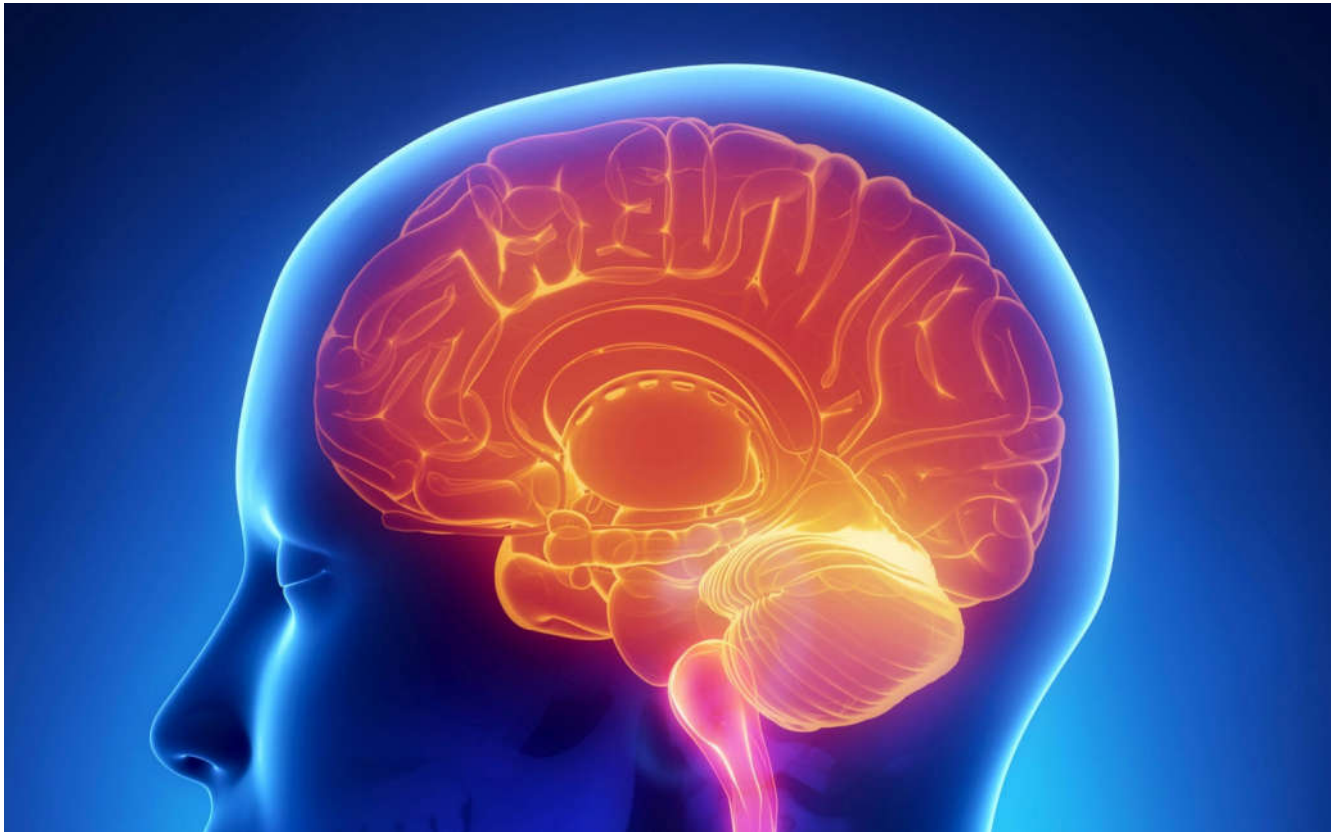



International Journal Of
**Recent Scientific
Research**

ISSN: 0976-3031

Volume: 6 (12) December -2015

CUTANEOUS HORN ON GLANS PENIS: A RARE PRESENTATION

Amit M Mungarwadi, Vikram Prabha,
Shrikanth P, Shridhar Ghagane and
Murigendra Hiremath



THE OFFICIAL PUBLICATION OF
INTERNATIONAL JOURNAL OF RECENT SCIENTIFIC RESEARCH (IJRSR)
<http://www.recentscientific.com/> recentscientific@gmail.com

CASE REPORT

CUTANEOUS HORN ON GLANS PENIS: A RARE PRESENTATION

Amit M Mungarwadi^{1*}, Vikram Prabha², Shrikanth P³, Shridhar Ghagane⁴ and Murigendra Hiremath⁵

^{1,2,3} Department of Urology, KLE Kidney Foundation, Dr. Prabhakar Kore Hospital & MRC KLE University's JN Medical College, Belgaum, India

^{4,5} PG Department of Studies in Biotechnology and Microbiology, Karnatak University, Dharwad, India

ARTICLE INFO

Article History:

Received 06th September, 2015

Received in revised form 14th October, 2015

Accepted 23rd November, 2015

Published online 28st December, 2015

Key words:

Cutaneous horn, underlying lesion, surgical excision.

ABSTRACT

This report presents a case of a 58 year old man with 2 penile cutaneous horns. Cutaneous hornarises from sun exposed areas with many underlying etiologies, one third being malignancy. The occurrence of cutaneous horn on penis is rare. Standard treatment involves wide surgical excision, but presence of underlying malignancy mandates partial penectomy.

Copyright © Amit M Mungarwadi, et al., 2015, This is an open-access article distributed under the terms of the Creative Commons Attribution License, which permits unrestricted use, distribution and reproduction in any medium, provided the original work is properly cited.

INTRODUCTION

Cutaneous horn on glans penis is a rare disease. Mostly it affects elderly in and often arises over sun exposed areas.¹ The horn is frequently conical, made of stratum corneum. Cutaneous horn occurs in coalition with or as a reaction to a wide variety of underlying benign, premalignant and malignant skin diseases. Here we report a rare presentation of cutaneous horn over penis.

Case report

A 58-year-old man presented with nodules over his penis since months. He had no pain, itching or discharge. He had a History of circumcision for long standing phimosis 6 months back. Examination revealed two nodules on his glans penis. The larger one measured 2cm x1 cm and the smaller about 0.5x0.5 cm (figure 1). There was no inguinal lymph adenopathy. Both nodules were excised with a rim of normal tissue and primary closure was achieved (figure 2). Postoperative recovery was uneventful. Histopathology of the nodules revealed extreme hyperkeratosis, dyskeratosis, and acanthosis. Although there was no focus of malignancy there were a few areas showing squamous atypia.




Figure 1 Preoperative image showing 2 cutaneous horns

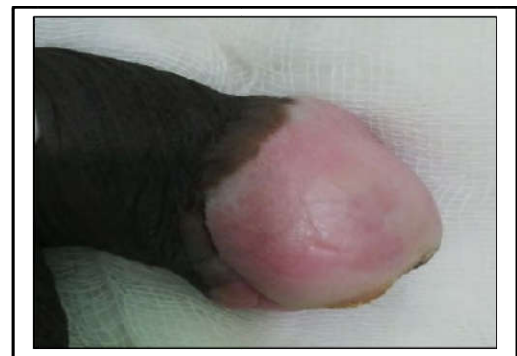

Figure 2 post-operative images after surgical excision of the cutaneous horns

*Corresponding author: **Amit M Mungarwadi**

Department of Urology, KLE Kidney Foundation, Dr. Prabhakar Kore Hospital & MRC KLE University's JN Medical College, Belgaum, India

DISCUSSION

Cutaneous horns are rarely seen in areas not exposed to sunlight. Various lesions seen at the base of a cutaneous horn include squamous cell carcinoma, actinic keratosis, keratoacanthoma, Bowen's disease, seborrheic keratosis and basal cell carcinoma.² The first case of a cutaneous horn was described in 1854, and since then less than 100 cases have been reported.⁴ The etiology of penile horns is uncertain, although they are often found in association with warts, phimosis, naevi and in areas associated with trauma. Malignant change should be suspected in a rapidly growing lesion. Treatment options include wide surgical excision with careful histological examination to exclude a focus of malignancy. If malignancy is present in a penile cutaneous horn, the treatment involves partial penectomy with or without regional lymph node dissection. Therapy with carbon dioxide or Neodymium YAG laser is used for patients who refuse surgery.³ while preliminary studies with laser are encouraging, partial penectomy remains the gold standard. Cutaneous horn can be preceded by circumcision between 2 months and 1 year, as in this case after a long period of phimosis³.

CONCLUSION

Cutaneous horn usually appears in exposed zones, but may also present on the penis. It is unique and multiple lesions are rare.

How to cite this article:

Amit M Mungarwadi *et al.*, Cutaneous Horn On Glans Penis: A Rare Presentation. *International Journal of Recent Scientific Research* Vol. 6, Issue, 12, pp. 7670-7671, December, 2015

It shows a tendency to develop local malignant neoplasia as squamous cell carcinoma in situ or basal cell carcinoma, and it is unusual for cutaneous horn to present as a metastatic cutaneous tumor. Cutaneous horn is more often found to be malignant in the penis than in other locations, at 33-37%⁵ & hence immediate treatment becomes mandatory.³

References

1. Lever FW, Schaumburg LG. Histopathology of the skin. 6th Ed, New York: JB Lippincott Co.; 1984.
2. De la Pena Zarzuelo E, Caero Rubias C, Sierra E, Delgado JA, SilmiMoyano A, Resel Estevez L. Cutaneous horn of the penis. *Arch Esp Urol* 2001; 54:367-8.
3. Lowe FC, McCullough AR. Cutaneous horns of the penis - an approach to management. Case report and review of literature. *J Am Acad Dermatol* 1985; 13:369-73.
4. Jewett PA. A case of horn on the glans penis. *New York Medical Times* 1854; 3:9.
5. Conde Sa'nchez JM, Rico Lo'pez J, Blasco Herna'ndez P, Espinosa Olmedo J, Domínguez omínguez M, Garcí'a Pe'rez M. Penile cutaneous horn. A clinical case. *Actas Urol Esp* 2000; 24: 182-4.

ISSN 0976-3031



9 770976 303009 >