



ISSN: 0976-3031

Available Online at <http://www.recentscientific.com>

CODEN: IJRSFP (USA)

International Journal of Recent Scientific Research  
Vol. 10, Issue, 07(D), pp. 33570-33572, July, 2019

**International Journal of  
Recent Scientific  
Research**

DOI: 10.24327/IJRSR

## Research Article

### EVALUATION OF VARIATION IN ROOT CANAL MORPHOLOGY OF MANDIBULAR ANTERIORS USING CONE BEAM COMPUTED TOMOGRAPHY

Mandavi Waghmare., Ayushi Sett., Sandeep Pagare., Hemant Bhutani., Kapil Gavand., Chintan Shah and Resha Shah

D Y Patil University, School of Dentistry, Nerul, Navi Mumbai-400706

DOI: <http://dx.doi.org/10.24327/ijrsr.2019.1007.3696>

#### ARTICLE INFO

##### Article History:

Received 10<sup>th</sup> April, 2019  
Received in revised form 2<sup>nd</sup> May, 2019  
Accepted 26<sup>th</sup> June, 2019  
Published online 28<sup>th</sup> July, 2019

##### Key Words:

Mandibular anteriors, root canal morphology, vertucci classification, bifurcated canal.

#### ABSTRACT

**Introduction:** A thorough knowledge of the anatomy of the root canals is one of the important factor for a successful root canal treatment. The same can be known easily through 3D imaging. A CBCT of the concerned tooth will give the dentist exact knowledge of the root canal anatomy and may subsequently reduce the number of root canal failures.

**Aims:** The aim of the study was to determine the prevalence of more than one canal in mandibular anterior teeth with the help of CBCT scans.

**Materials and Method:** 616 permanent mandibular anterior teeth, were evaluated on CBCT scans for the varied morphology of the root canals.

**Result:** 25.48% of mandibular anteriors had more than 1 canal. Higher prevalence of two canals was found in males as compared to females. Most of the teeth had Type I configuration followed by Type II and Type IV.

**Conclusion:** Mandibular anterior teeth show a large amount of variation in root canal anatomy. The CBCT's help us understand the morphology better by giving us insight into a third dimension. Our study stresses on the importance of taking a CBCT in cases of root canal treatment to reduce the number of root canal failures.

Copyright © Mandavi Waghmare *et al*, 2019, this is an open-access article distributed under the terms of the Creative Commons Attribution License, which permits unrestricted use, distribution and reproduction in any medium, provided the original work is properly cited.

#### INTRODUCTION

For a Dental practitioner, knowledge of the root canal morphology, and any variations it might have, is essential to predict the prognosis of root canal treatment. Endodontic treatment not only prevents but may also cure endodontic disease and apical periodontitis.

Ingle lists the most frequent cause of endodontic failure as apical percolation and subsequent diffusion stasis into the canal.<sup>1</sup> Complete debridement and obturation of the root canal system is a key factor for successful endodontic treatment.<sup>2</sup>

Inadequate knowledge about the root canal anatomy may lead to improper or incomplete cleaning, shaping an obturation thus leading to failure of root canal treatment. Accessory canals, bifurcation or additional canals are often difficult to identify using imaging modalities like IOPA or an OPG (Orthopantomogram), thus creating difficulty in carrying out a successful endodontic treatment.

Although some of the morphological variations may depend on different ethnic backgrounds, two canals should be expected in

about one-quarter for mandibular incisors. This proportion is not found clinically by practitioners during root canal treatment due to the failure of the dentist to recognize the presence of the second canal.<sup>3,4</sup>

Therefore, in these situations, taking a CBCT of the concerned tooth will not just give the dentist exact knowledge of the root canal anatomy but may subsequently reduce the number of root canal failures.

With this understanding we carried out a study with the aim to determine the prevalence of two canals in mandibular anterior teeth with the help of Cone beam computed tomography (CBCT) scans. The objectives were

- To accurately identify the number of canals in the mandibular anterior teeth and establish the prevalence of more than one canal to improve the success rate of root canal treatments.
- Comparative study of the prevalence amongst males and females

\*Corresponding author: Mandavi Waghmare

D Y Patil University, School of Dentistry, Nerul, Navi Mumbai-400706

- Comparative study of the prevalence of 2 canals between mandibular central incisors, lateral incisors and canines.
- Comparative study of the prevalence of 2 canals based on Vertucci's classification.

Vertucci in 1984 classified the canal configuration of mandibular incisors into 8 types: <sup>5</sup>

- **Type I:** a single canal from pulp chamber to the canal terminus (1-1 configuration)
- **Type II:** two separate canals leaving the chamber, but merging short of the canal terminus to form a single canal (2-1 configuration)
- **Type III:** a single canal that divides into two and subsequently merges to exit as one (1-2-1 configuration)
- **Type IV:** two distinct canals from pulp chamber to the canal terminus (2-2 configuration)
- **Type V:** a single canal leaving the chamber and dividing into two separate canals at the canal terminus (1-2 configuration)
- **Type VI:** two separate canals leaving the pulp chamber, merging in the body of the root, and dividing again into two distinct canals short of the canal terminus (2-1-2 configuration)
- **Type VII:** a single canal that divides, merges and exits into two distinct canals short of the canal terminus (1-2-1-2 configuration)
- **Type VIII:** three distinct canals from pulp chamber to the canal terminus (3-3 configuration).

**MATERIALS AND METHOD**

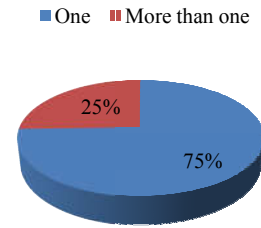
This was a retrospective study done on archives of CBCT scans of mandibular anterior region of 150 patients, taken for routine dental treatment. The study was carried out at the department of oral medicine and radiology at D Y Patil School of Dentistry, Navi Mumbai. A total of 616 permanent mandibular anterior teeth were evaluated to determine the morphology of the root canal. Teeth with pathologies like internal and/or external root resorption, fractured roots, and incompletely formed roots were excluded from the study. The root canals of the mandibular anteriors were observed on sagittal and para-axial section by single observer and the morphological variations were noted as per the vertucci's classification.

**RESULTS**

A total of 150 scans were evaluated for morphological variations in root canals of mandibular anteriors. Of the 150 scans 83 were male patients and 64 were female patients. A total of 616 teeth were observed. In the total 616 teeth considered, 25.48% had more than 1 canal. That is, 1 in every 4 teeth we evaluated had a second canal.

A total of 263 canines were evaluated in the study, of which 14.1% had more than 1 canal.

213 lateral incisors were considered of which 34.7% showed more than 1 canal and 140 central incisors were studied of which 32.9% had more than 1 canal. That is, the incisors showed twice the likelihood of having 2 canals (Table 1).



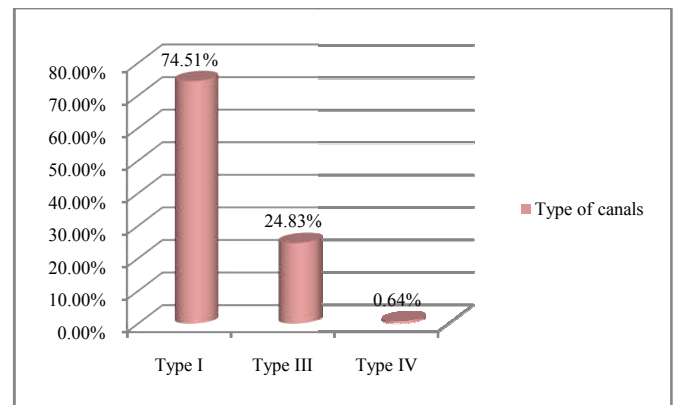
**Graph 1** Pie diagram showing the distribution of single and more than one canal in the samples.

**Table 1** Frequency of two canal in the incisors and canine

Tooth	No. of canals	n	%
Canines Total -263	One	226	85.9
	More than one	37	14.1
Lateral incisors Total - 213	One	139	65.3
	More than one	74	34.7
Central incisors Total - 140	One	94	67.1
	More than one	46	32.9

**Table 2** Distribution of more than one canal in the different tooth under observation

Tooth no.	No. of canals	n	%
43 Right Canine	One	122	90.4
Total - 135	More than one	13	9.6
33 Left Canine	One	104	81.3
Total - 128	More than one	24	18.8
42 Right Lateral	One	72	66.1
Total - 109	More than one	37	33.9
32 Left Lateral	One	67	64.4
Total - 104	More than one	37	35.6
41 Right Central	One	49	69.0
Total - 71	More than one	22	31.0
31 Left Central	One	45	65.2
Total - 69	More than one	24	34.8



**Graph 2** Distribution of canal as per Vertucci's classification.

We found that as per Vertucci's classification, the frequency of Type 1 canal was highest at 74.51% followed by type III which was 24.83% and type IV was the least at 0.64%. No other configuration of canals was observed in our sample.

Among the males and females we found 16.20% of males with 2 canals and in females it was recorded at 11.30%. Thus a higher frequency of two canals was observed among male patients.

## DISCUSSION

A thorough knowledge of the root canal system makes it easy to proceed with the root canal treatment. Problems encountered during and after the treatment are due to inadequate knowledge of the root canal morphology. In the past various methods such as tooth sectioning, filling up the canals with radio-opaque materials and taking cross-sectional radiographs were used to understand the morphological variations in the root canals of teeth. With the advent of 3D imaging it is easier to analyze the tooth morphology in three dimensions and study the variations. CBCT provides a better resolution, and gives precise qualitative and quantitative measurements of anatomical details.

Vertucci in 1974 studied 300 mandibular incisors and found 30% mandibular incisors with two canals.<sup>6</sup> This study was carried out by sectioning the tooth. A literature review by Kartal *et.al* 1992 reveals the prevalence of second canal in permanent mandibular incisors between 11.5-45%.<sup>7</sup> In our study we found the prevalence of second canal at 25.48%.

A study by Gaurav RV *et.al.* (2017) in Indian population showed the prevalence of second canals as follows: right central incisor- 33.5%, left central incisor- 30%, right lateral incisors- 33.5% and left lateral incisor-36.5%<sup>8</sup>. Our results are in approximation of the study conducted by Gaurav RV *et.al* (Table 2). In the same study they found frequency of two root canals in 15.2% of men and 20.4% of women, where as in the present study we found the frequency at 16.20% and 11.30% respectively, thus both the studies have recorded higher prevalence among males. In a review by Hugo P. *et.al* in 2017 on 25 other reports, published between the years 2000 and 2017, found that the variation has a strong preference for the female sex<sup>9</sup>. Contrary to this, we found a higher prevalence in males as compared to females.

In a study by Boruah LC and Bhuyan AC on north east Indian population they found the Vertucci type frequency of canal as follows Type I 63.75%, Type III 22.9%, Type II 7.08% and Type V 6.25%<sup>10</sup>. In the Iranian study by Sina Haganifar *et al.* the frequency of the various types were Type I, type III, type II, type V, and type VI, respectively. In terms of the characteristics investigated, bilateral symmetry was observed. In a study by Brizuela C (2018), type I canal configuration in Chilean population was 77.78% and in Belgian population it was 61.49%. while Zhengyar *et al* found 96.25% of type I configuration in Chinese population. Our study too recorded Type I variety at 74.51% which is in accordance to the Chilean and Belgian population. Type III (24.83%) and Type IV (0.64%) configuration were the next common configuration of root canal system. No other canal configurations were observed in our study.

## CONCLUSION

Root canal failures create not only a lot of unnecessary stress for the patients but also for the dentist concerned. Increased awareness about the presence of 2 canals among clinicians for mandibular anterior teeth will help reduce the number of Root Canal failures.

As we can clearly see from the results, mandibular anterior teeth show a large amount of variation in root canal anatomy. With the advent of CBCT, it has helped us understand the morphology better by giving us insight into a third dimension which was not available earlier.

Our study thus stresses on the importance of taking a CBCT in cases of root canal treatment to know the anatomy of the tooth better and reduce the number of root canal failures and predict the prognosis of the endodontic treatment.

## References

1. Ingle JJ. Endodontic, 3rd ed. Philadelphia: Saunders; 1985
2. Rahimi S, Milani AS, Shahi S, Sergiz Y, Nezafati S, Lotfi M. Prevalence of two root canals in human mandibular anterior teeth in an Iranian population. *Indian J Dent Res* 2013; 24:234-6.
3. Miyashita M, Kasahara E, Yasuda E, Yamamoto A, Sekizawa T. Root canal system of the mandibular incisor. *J Endod* 1997; 23(8):479-84.
4. Slowey RR. Root canal anatomy. Road map to successful endodontics. *Dent Clin North Am* 1979;23(4):555-73
5. Vertucci FJ. Root canal anatomy of the human permanent teeth. *Oral Surg, Oral Med, Oral Pathol.* 1984; 58:589-99.
6. Vertucci FJ. Root canal anatomy of mandibular anterior teeth. *J Am Dent Assoc* 1974; 89(2): 369-71.
7. Kartal N, Yanikoglu F. Root canal Morphology of mandibular incisors. *J Endod* 1992 Nov, 18(11): 562-64.
8. Gaurav RV, Bhadange C, Bhoosreddy AR, Vedpathak PR, Mehrotra GP, Nerkar AC *et.al.* Cone beam computed tomography study of root canal morphology of permanent mandibular incisors in Indian sub-population. *Pol J Radiol* 2017, 82: 371-75.
9. Plascencia H, Cruz A, Gascon G, Ramirez B, Diaz M. Mandibular canines with two roots and two root canals: case report and literature review. *Case Rep Dent* 2017 doi.org/10.1155/2017/8459840.
10. Boruah LC, Bhuyan AC. Morphologic characteristics of root canal of mandibular incisors in North-East Indian population: An *in vitro* study. *J Conserv Dent.* 2011; 14(4): 346-350.
11. Haghani S, Moudi E, Bijani A, Ghanbarabadi MK. Morphologic assessment of mandibular anterior teeth root canal using CBCT. *Acta Medica Acad* 2017; 46(2):85-93.

### How to cite this article:

Mandavi Waghmare *et al.*, 2019, Evaluation of Variation In Root Canal Morphology of Mandibular Anteriors Using Cone Beam Computed Tomography. *Int J Recent Sci Res.* 10(07), pp. 33570-33572. DOI: <http://dx.doi.org/10.24327/ijrsr.2019.1007.3696>

\*\*\*\*\*