



ISSN: 0976-3031

Available Online at <http://www.recentscientific.com>

CODEN: IJRSFP (USA)

International Journal of Recent Scientific Research
Vol. 9, Issue, 7(D), pp. 27953-27955, July, 2018

**International Journal of
Recent Scientific
Research**

DOI: 10.24327/IJRSR

Research Article

A CASE STUDY OF LANTANA CAMARA POISONING IN SIROHI GOAT

Virendra Singh¹, Manish Agrawal², Nagda³ R K., Sharma M. C⁴ and Anil Mordia⁵

¹ Livestock Research Station, Bojunda, Chittorgarh-312001

²Department of Veterinary Pathology, PGIVER, Jaipur

³ Officer Incharge, Livestock Research Station, Bojunda, Chittorgarh-312001

⁴Department of LPM, CVAS, Navania, Vallabhnagar, Udaipur-313601

⁵ Livestock Research Station, Dag, Jhalawar (RAJUVAS, Bikaner)-326514

DOI: <http://dx.doi.org/10.24327/ijrsr.2018.0907.2364>

ARTICLE INFO

Article History:

Received 4th April, 2018

Received in revised form 25th

May, 2018

Accepted 23rd June, 2018

Published online 28th July, 2018

Key Words:

Lantana camara, Goat, Toxicity and
Photosensitization

ABSTRACT

In present report, secondary photosensitization due to Lantana camara toxicity in kid of Sirohi goat in Chittorgarh district of Rajasthan is discussed. Among poisonous plants, Lantana camara is a common noxious weed widely known to cause phototoxicity in large and small ruminants. The major clinical manifestations shown by affected kids were anorexia, depression, isolated from herds, swelling of eye lids and later on sloughing of superficial layer of skin particularly over the back, on ventral abdomen, neck, around eyes, udder and tail along with tendency of itching. Symptomatic clinical treatment comprised of oral administration of activated charcoal, purgative and liver tonic supported with electrolyte therapy and parental administration of antihistaminic and vitamin B-complex with liver extract was given.

Copyright © Virendra Singh et al, 2018, this is an open-access article distributed under the terms of the Creative Commons Attribution License, which permits unrestricted use, distribution and reproduction in any medium, provided the original work is properly cited.

INTRODUCTION

Lantana camara is one of the most commonly known noxious weed distributed worldwide (Kumar et al., 2016). Toxic plants are of major concern to animal husbandry because of their harmful effects to livestock health and reduction in productivity. Among poisonous plants, *Lantana camara* is a common noxious weed (Sharma et al., 1988) widely known to cause phototoxicity in small and large ruminants (Annalize Ide et al., 1998; Black et al., 1985). It is widely available in the Aravali ranges of Rajasthan (India) and commonly known as 'Buti' (Kachhawaha et al., 2014). Its poisoning in animals has been documented from different parts of world including India. Young animals, newly exposed to pastures and unfamiliar to forage varieties are most prone to such toxicities. The toxicity is due to accumulation of photodynamic agent in peripheral circulation either through ingestion, absorption through skin or by abnormal metabolism (Radostits et al., 2003; Casarett and Doull, 2001). The principal toxic component of this weed is Lantadenes (Sharma et al., 2007) which are pentacyclic triterpenoids that leads to hepatotoxicity, photosensitization and jaundice (Kumar et al., 2016).

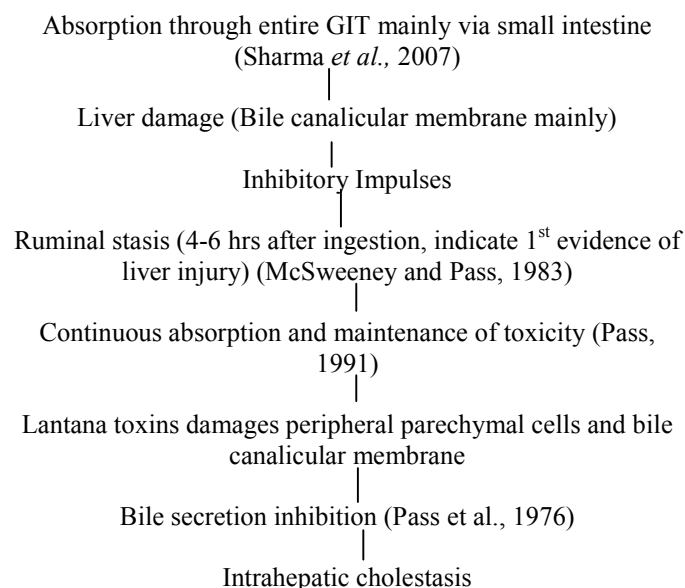


Fig 1 Flow chart of absorption and mechanism of action of lantades

Almost 24 hours after return from pastures last evening, one affected kid was anorexic and isolated from the herd showing

*Corresponding author: **Virendra Singh**
Livestock Research Station, Bojunda, Chittorgarh-312001

early clinical symptoms of lantana poisoning at Livestock Research Station, Bojunda, Chittorgarh. With passage of time superficial layers of skin was found sloughed off particularly over the back, on ventral abdomen, neck, around eyes, udder and tail along with tendency of itching (Fig. 2 and 3). Examination of pastures and feed stores was carried out and presence of weed in the pastures was confirmed. No such changes were noticed in adult animals by second day or later.

There was recorded history of mortality in a kid of five months that died due to Lantana toxicity wherein initial symptoms of anorexia, depression, fever, redness of muzzle, swelling of eyes and at base of ear were noticed following which there were cracks on muzzle and sloughing of skin over the ears and other dorso-lateral parts of body. The kid could not be recovered and died after seven days. Necropsy examination of carcass showed discoloured (yellowish) and swollen liver with distended gall bladder, swollen and pale kidneys were observed indicative of death due to lantana toxicity. Presence of distended gall bladder and discoloured liver were in accordance with earlier findings reported by Annalize Ide *et al.* (1998) and Sharma *et al.* (1981).

Since no antidote to lantana toxicity is available so symptomatic clinical treatment was initiated with oral administration of activated charcoal supported with electrolyte therapy and parental administration of antihistaminic and vitamin B-complex with liver extract for 5 days. Oral administration of magnesium sulphate was also initiated from 2nd day onwards and liver tonic was given till 7th day. Affected kids were kept in dark and cool shady place to reduce itching and photosensitization.



Fig 4 Trees of *Lantana camara* in flowering stage



Fig 2 Sloughing off skin over ears and neck region in Sirohi kid



Fig 3 Sloughing off skin over ears, neck and dorsum in Sirohi kid

Affected goat kid recovered after treatment. Feed and water intake was restored to normal. It was concluded from the case study that young animals, newly exposed to pastures and unfamiliar to forage varieties are more prone to lantana toxicity. Ingestion of lantana leads to sluggish rumen microbial activity in ruminants which causes anorexia and depression. Similar clinical signs were also described by Sharma *et al.* (1981), Ekambaram *et al.* (2014) and Bhardwaj *et al.* (2012). Sloughing of superficial layer of skin in lantana toxicity was also reported by Patel *et al.* (2012). Clinical manifestations in present study are in agreement with those described earlier by Kachhawaha *et al.* (2014).

A combined therapy consist of oral administration of activated charcoal, purgative and liver tonic supported with electrolyte therapy and parental administration of antihistaminic and vitamin B-complex with liver extract for 5-7 days can be helpful in treatment of Lantana toxicity. The activated charcoal adsorbs toxic components of Lantana and purgatives help to remove the toxic components from gastrointestinal tract. Electrolyte therapy and administration of liver tonic helps restoring the liver functions. Keeping the animals in dark shady place helps reducing the photosensitizing potential of toxic principles. Oral administration of activated charcoal has been described earlier for treatment of lantana toxicity by Ekambaram *et al.* (2014) and Pass and Stewart (1984). Kumar *et al.* (2009) reported that successful management of lantana poisoning in an organized sheep farm by a combined treatment comprised of liver tonic, anti-histaminic, rumenotonic and dextrose.

Toxic plants are of major concern to veterinarians because of their harmful effects to livestock in terms of causing mortality and reduction in productivity (Sharma *et al.*, 2007 and Diaz, 2011). This plant shows change in inflorescence with age and season that's why very difficult to classify taxonomically (Munir, 1996).

References

- Bhardwaj, R.K., Bhadwal, M.S., Kumar, A. and Sharma, R. (2012). Acute Lantana poisoning in a flock of goats. *Indian Vet. J.*, 89(12): 85-86.
- Black, H. and Carter R.G. (1985). Lantana poisoning of cattle and sheep in New Zealand. *New Zealand Veterinary Journal*, 33(8): 136-137.
- Casarett and Doull's. (2001). Toxicology, The basic science of poisons. *McGraw Hill Medical Publishing Division*: 970.
- Diaz, G.J. (2011). Toxic plants of veterinary and agricultural interest in Colombia. *International Journal of Poisonous Plant Research*, 1: 1-19.
- Ekambaram, B., Chakravarthi, M.K. and Rajesh, M.M. (2014). Incidence of Lantana poisoning in Nellore sheep under farm conditions. *Indian Vet. J.*, 91(12): 80-82.
- Ide, A. and Tutt, C.L.C. (1998). Acute *Lantana camara* poisoning in a Boer goat kid. *Tydskr.S.Afr.vet.Ver.*, 69(1): 30-32.
- Kachhawaha, S., Kachhawaha, J., Srivastava, M., Chadha, B. and Shweta, K. (2014). Clinical findings, post mortem lesions and therapeutic management of *Lantana* toxicity in Ovines. *Intas Polivet*, 15(1): 112-114.
- Kumar, N.V., Reddy, Y.R. and Reddy, A.R.M. (2009). Lantana poisoning in an organised sheep farm and its management. *Intas Polivet*, 10: 71-72.
- Kumar, R., Katiyar, R., Kumar, S., Kumar, V. and Singh, V. (2016). *Lantana camara*: An alien weed, its impact on animal health and strategies to control. *Journal of Experimental Biology and Agricultural Sciences*, 4(3S): 321-337.
- McSweeney, C.S. and Pass, M.A. (1983). The mechanism of ruminal stasis in lantana poisoned sheep. *Quarterly journal of experimental physiology*, 68: 301-313.
- Munir, A.A. (1996). A revision taxonomic of *Lantana camara* L. and *L.montevicensis* Briq. (Verbenaceae) in Australia. *Journal of Adelaide Botanic Gardens*, 17: 1-27.
- Pass, M.A., Seawright, A.A. and Heath, T.J. (1976). Effect of ingestion of *Lantana camara* L. on bile formation in sheep. *Biochemical Pharmacology*, 25: 2101-2102.
- Pass, M.A. and Stewart, C. (1984). Administration of activated charcoal for the treatment of lantana poisoning of sheep and cattle. *J. Appl. Toxicol.* 4(5): 267-69.
- Pass, M.A. (1991). Poisoning of livestock by lantana plants. In: Handbook of Natural Toxins, Vol. 6, Toxicology of Plant and Fungal Compounds R. Keeler, and T. Anthony, eds., Marcel Dekker, Inc., New York. pp. 297-311.
- Patel, H.B., Modi, C.M., Mody, S.K., Patel, H.B. and Parekar, S.S. (2012). *Lantana camara* poisoning in Mehsana buffaloes: A profile of photosensitization. *Wayamba Journal of Animal Science*, 578X: 371 - 372.
- Radostits, O.M., Gay, C.C., Blood, D.C. and Hinchcliff, K.W. (2003). Veterinary Medicine. A Textbook of the diseases of cattle, sheep, pigs, goat and horses. *Book Power Publication*, 1685-1687.
- Sharma, O.P., Makkar, H.P.S. and Dawra, R.K. (1988). A review of the noxious plant *Lantana camara*. *Toxicol*, 26(11): 975-87.
- Sharma, O.P., Makkar, H.P.S., Dawra, R.K. and Negi, S.S. (1981). A review of the toxicity of *Lantana camara* (Linn) in Animals. *Clinical Toxicology*, 18(9): 1077-1094.
- Sharma, O.P., Sharma, S., Patabhi, V., Mahato, S.B. and Sharma, P.D. (2007). A review of the hepatotoxic plant *Lantana camara*. *Crit. Rev. Toxicol*, 37(4): 313-52.

How to cite this article:

Virendra Singh *et al.* 2018, A Case Study of Lantana Camara Poisoning in Sirohi Goat. *Int J Recent Sci Res.* 9(7), pp. 27953-27955. DOI: <http://dx.doi.org/10.24327/ijrsr.2018.0907.2364>
